

Peritonsillar Ultrasound:

Technical approach and spectrum of pediatric
peritonsillar infections

Anjum Bandarkar, MD

Children's National Health System, Washington, D.C.

Disclosures:

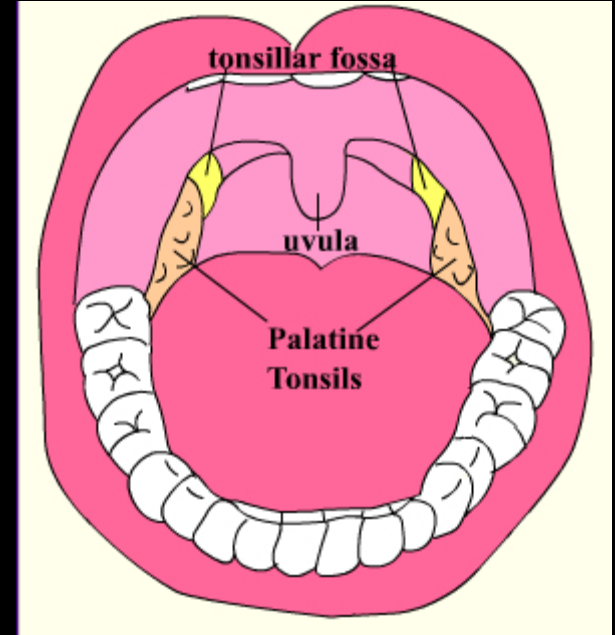
- None

Objectives:

- To describe the technique of performing transcutaneous ultrasound of the tonsil & peritonsillar region
- To illustrate the sonographic findings in the spectrum of pediatric peritonsillar infections
- To discuss our algorithm for management of peritonsillar abscess

Background:

- Peritonsillar infections are common, particularly in **adolescent** population.
- Peritonsillar abscess (PTA) is a **common deep neck infection** characterized by collection of purulent fluid between the **palatine tonsil** capsule medially and the fascia of the superior constrictor muscle laterally.



Background:

- Due to the similar clinical presentation, **differentiation of PTA** from **uncomplicated tonsillitis** can be very challenging based on clinical exam alone.
- This **distinction is critical** in the management because PTA needs needle drainage of pus or tonsillectomy and tonsillitis can be treated with antibiotics.

Intraoral versus Transcutaneous:

Intraoral Ultrasound (US):

- **Not well tolerated** in children due to trismus and size of intracavitary probe.
- May be used in adults.

Advantages of Transcutaneous Tonsil US:

- Readily available
- Much less frightening for children
- No radiation
- No sedation
- Quickly performed
- Eliminates need for topical anesthetic spray in oropharynx
- Relatively inexpensive

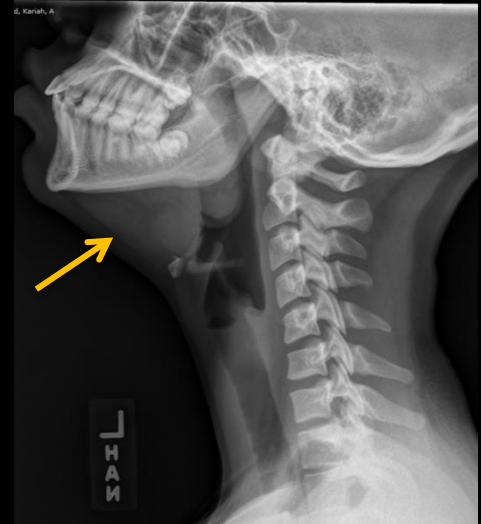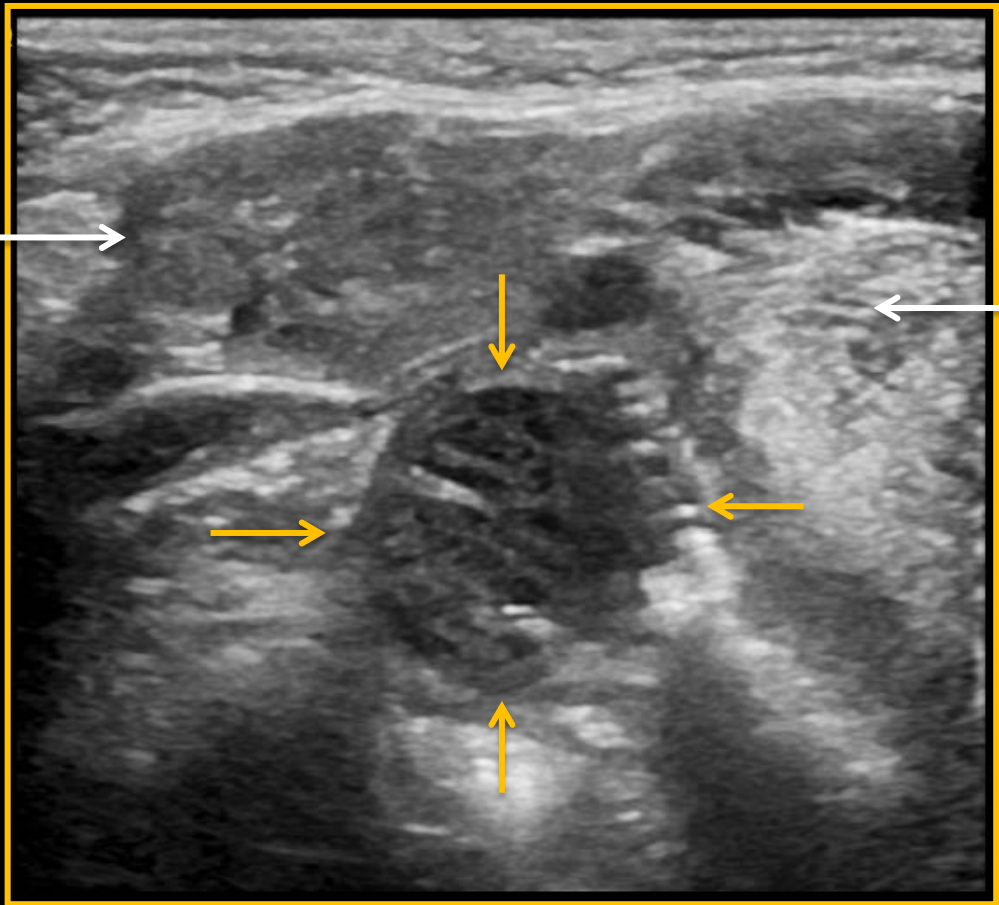
In our institution, we use tonsil ultrasound as the primary imaging modality to evaluate PTA.

Tonsil Ultrasound - Technique:

- Patient Position: Supine or sitting with neck extended
- Transducer: Linear high frequency transducer, typically 9 to 15 Mega Hertz
- Place transducer externally over the submandibular region of neck.

Tonsil Ultrasound - Technique:

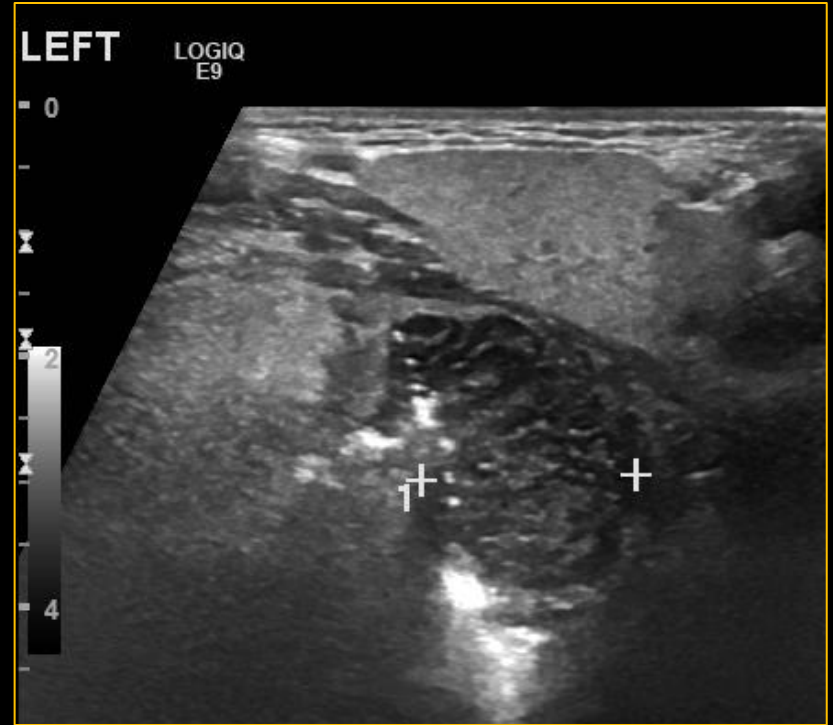
- Patient Position: Supine or sitting with neck extended
- Transducer: Linear high frequency transducer, typically 9 to 15 Mega Hertz
- Place transducer externally over the submandibular region of neck.
- Tonsil is found immediately deep to submandibular gland.



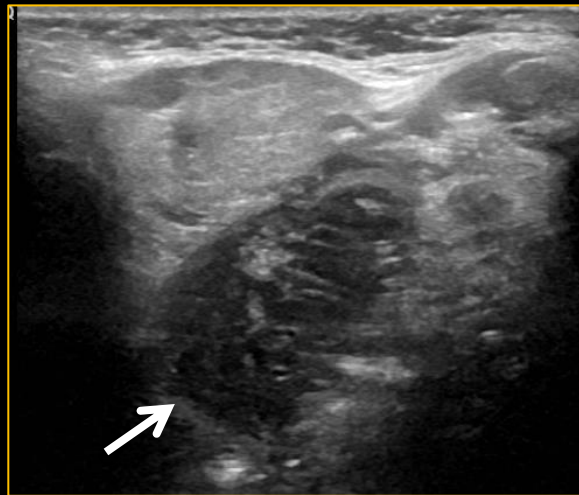
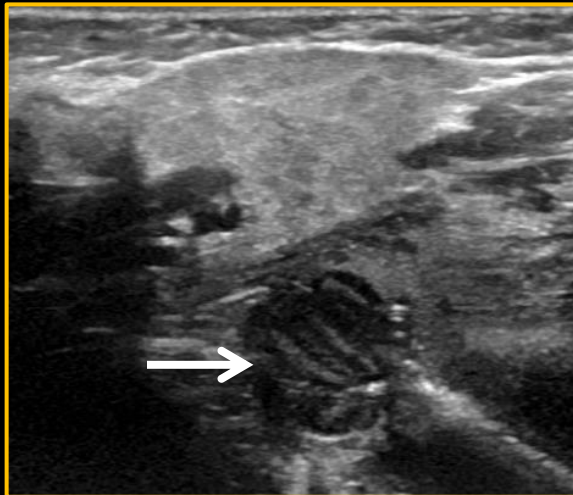
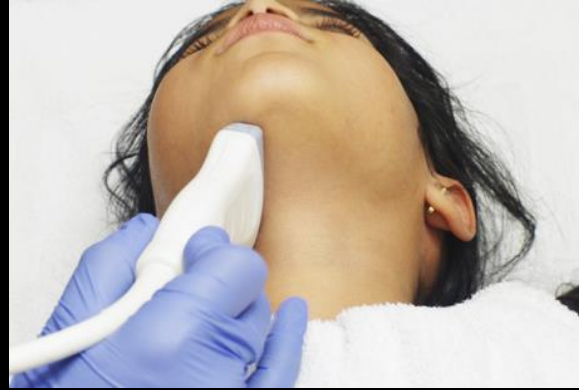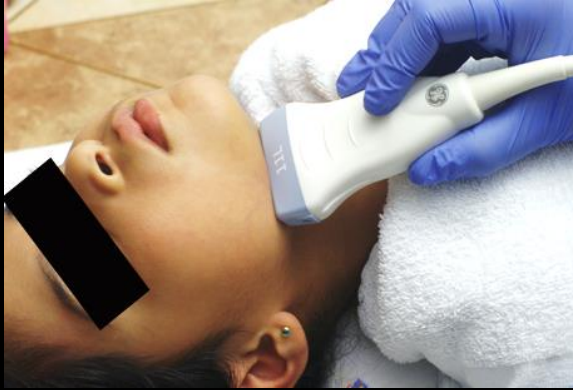Transverse image of **normal right tonsil**

What does the tonsil look like?

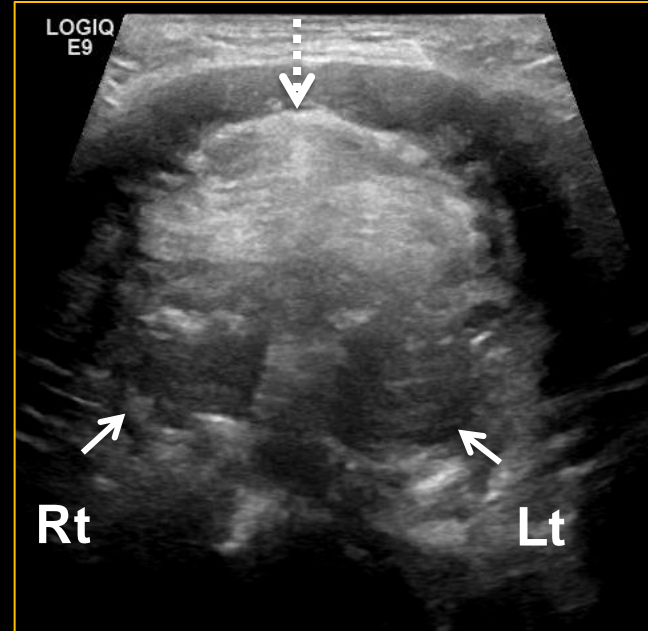
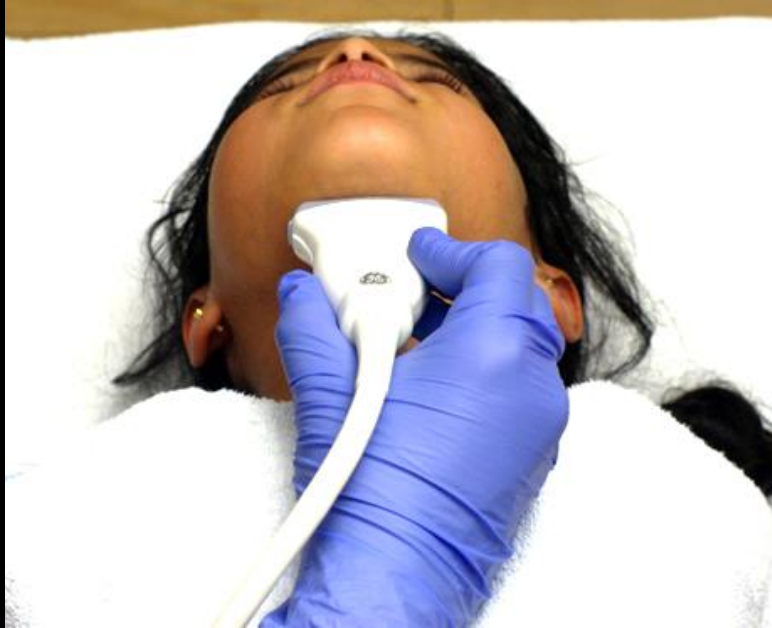- Ovoid soft tissue structure
- Subtly lobulated margins
- Striated parenchyma (crypts)
- Mobile specks of air medially



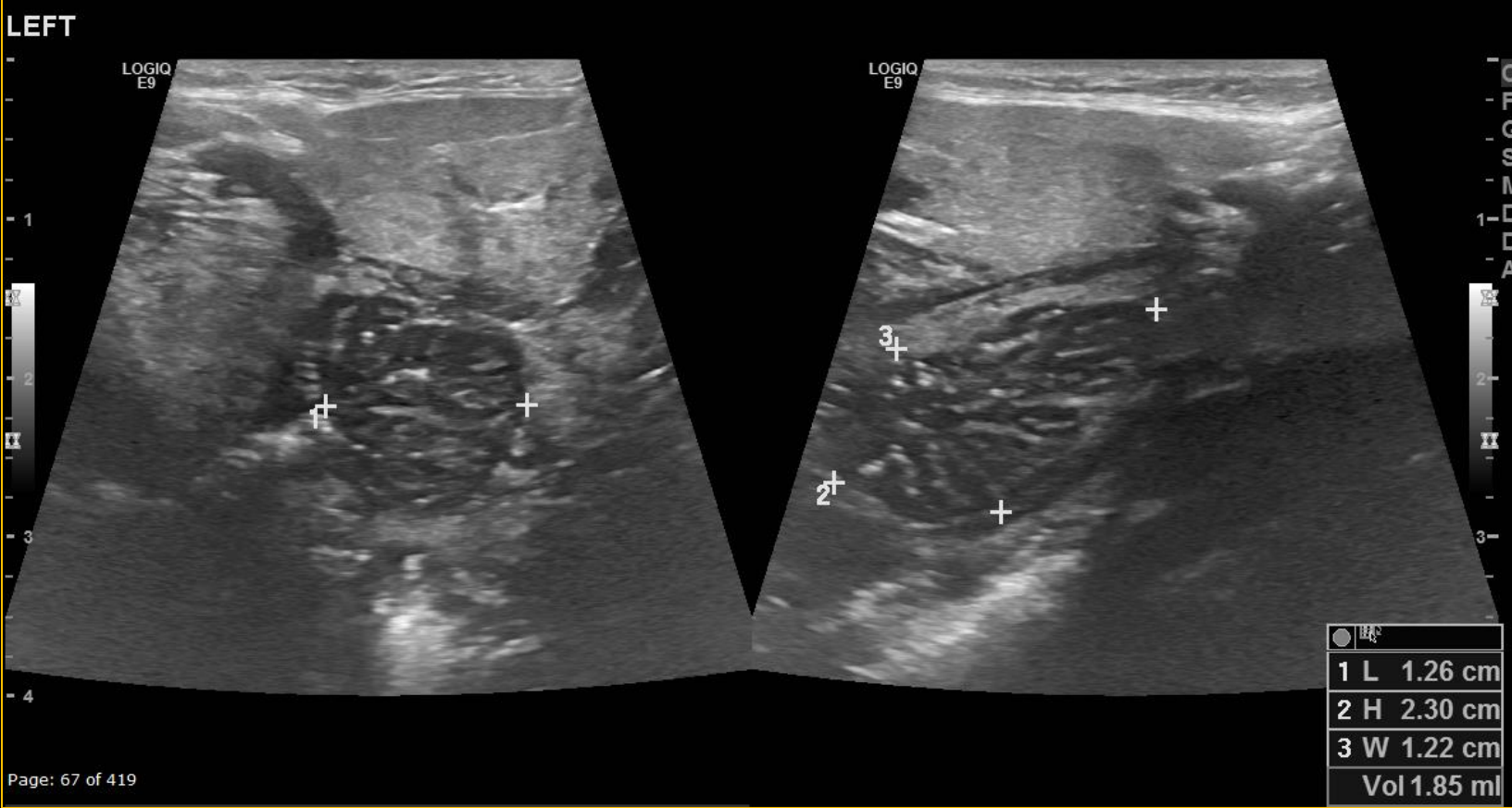
Tonsil US – Submandibular Approach:



Tonsil US – Midline Approach:



How to measure the tonsil?

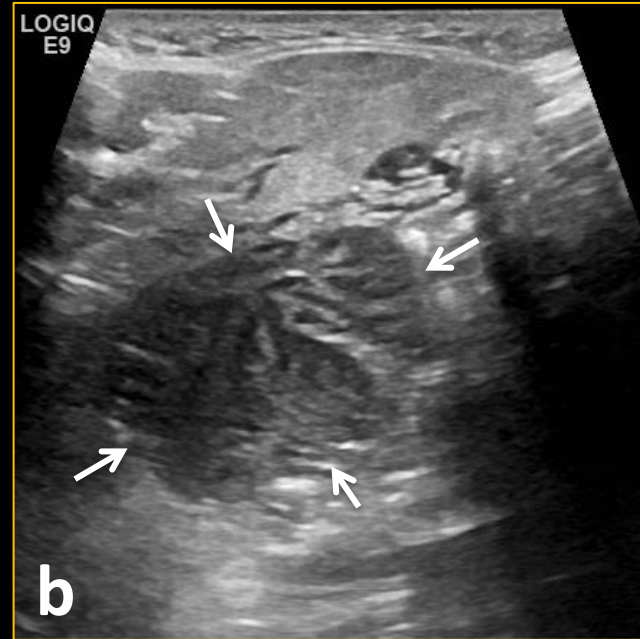
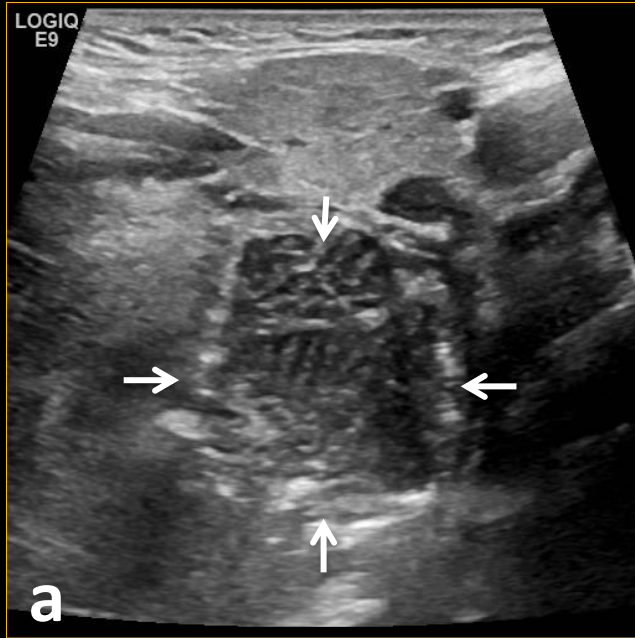


Spectrum of Peritonsillar Infections:

Sonographic findings could be classified as –

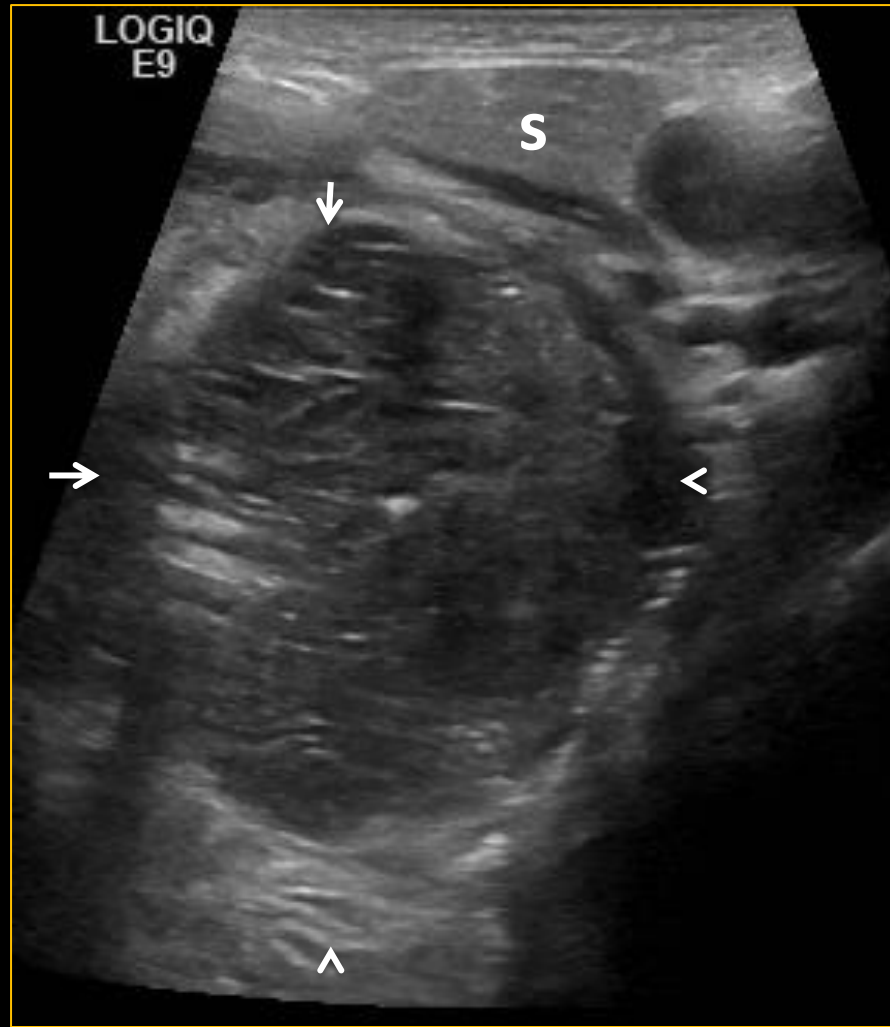1. Acute Uncomplicated Tonsillitis
2. Peritonsillar Cellulitis/Phlegmon
3. Intratonsillar Abscess
4. Peritonsillar Abscess
5. Parapharyngeal Abscess

Acute Tonsillitis



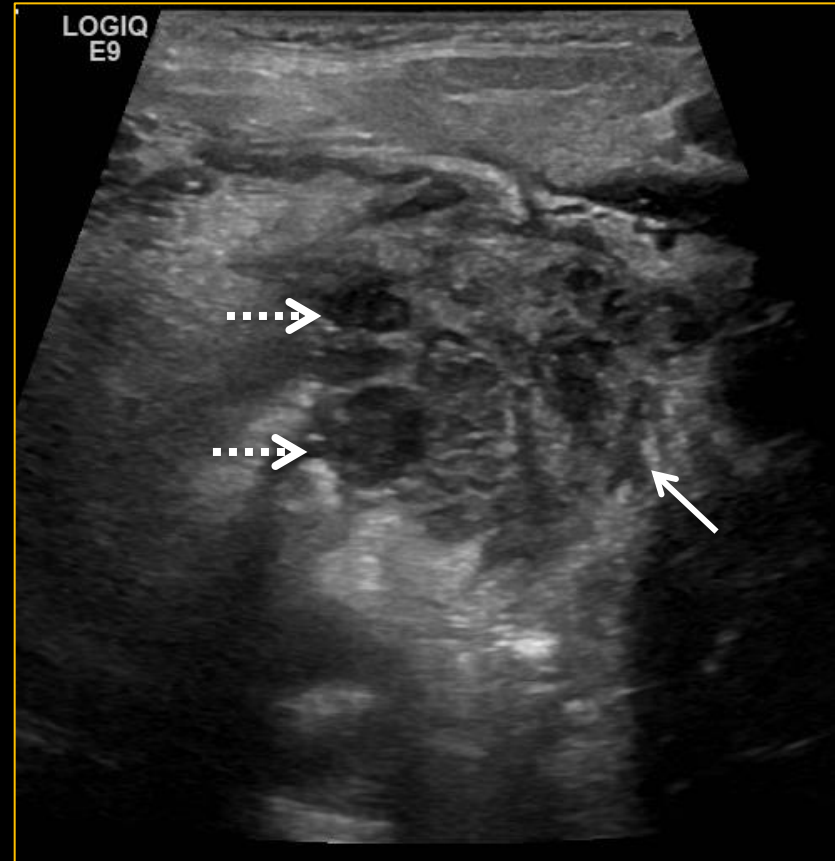
- Tonsillar enlargement
- Preserved echotexture

Acute Tonsillitis

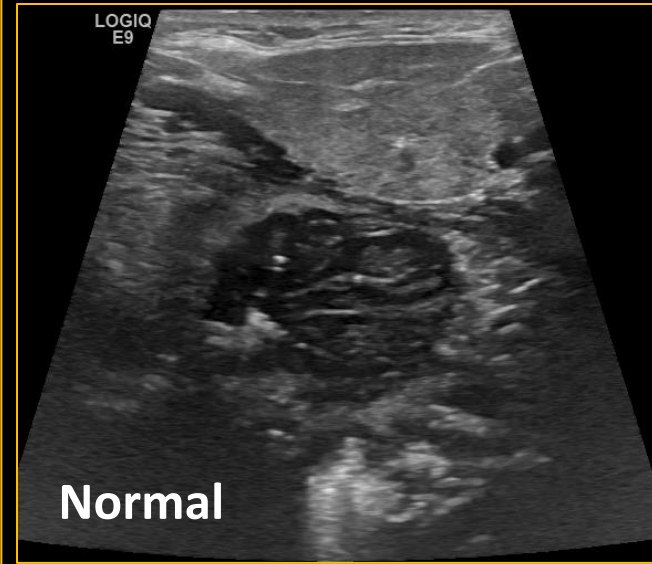
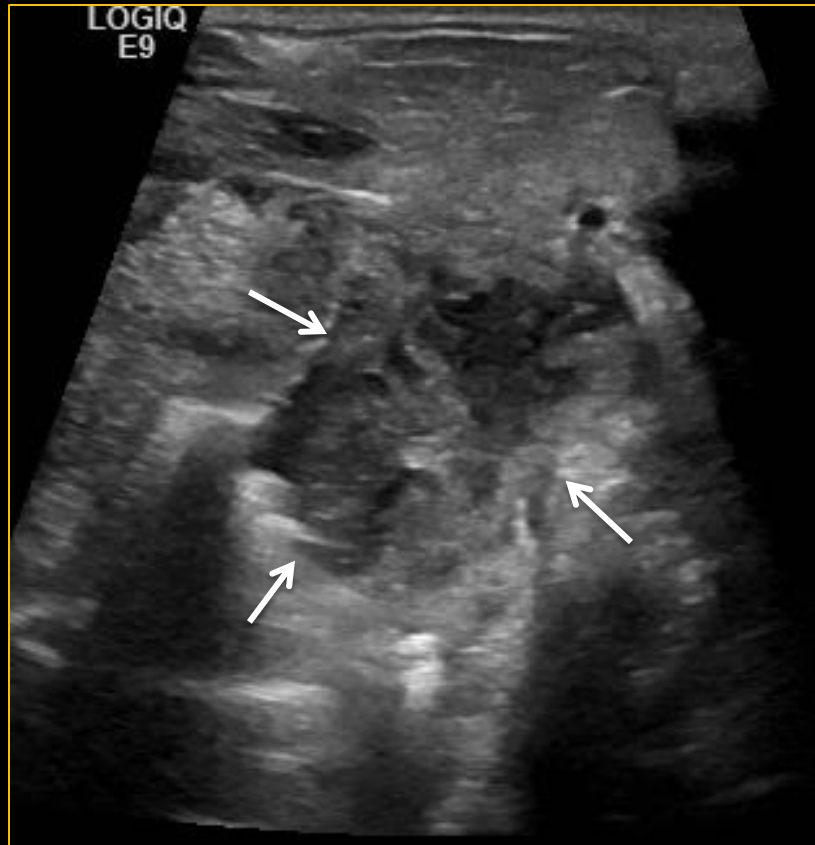


Peritonsillar Cellulitis:

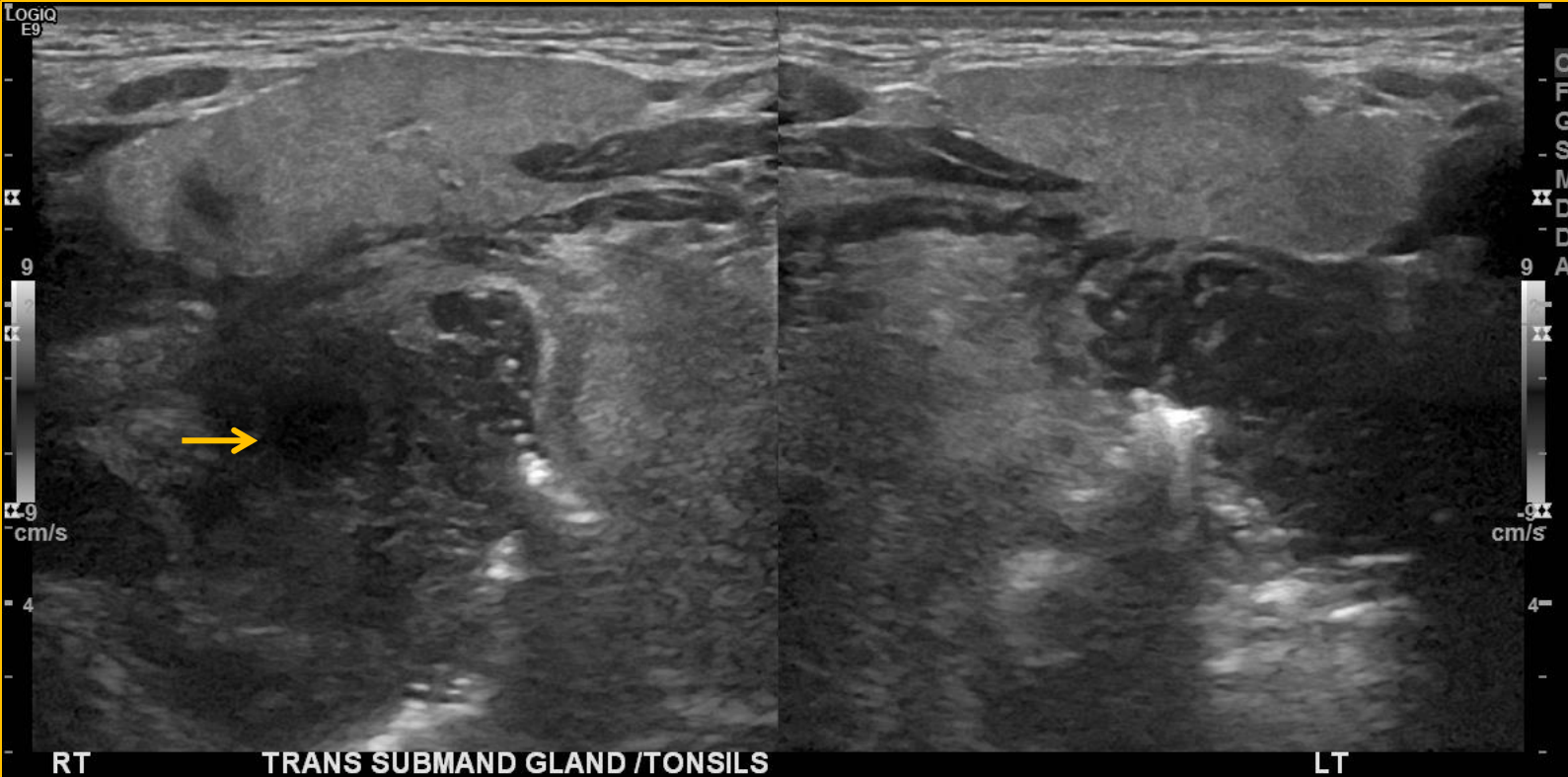- Heterogeneous parenchyma
- Increased perifocal edema
- Hypoechoic areas within
- Conservative management, reassess in 24 hours after starting antibiotics



Peritonsillar Cellulitis:

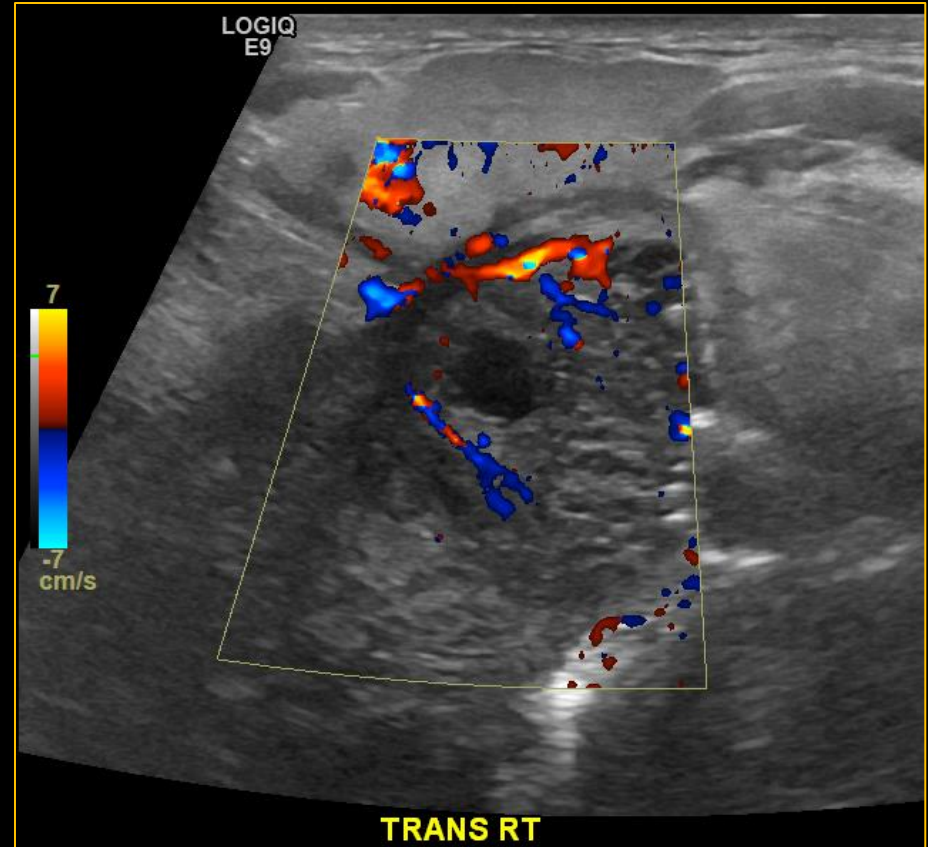


Intratonsillar Abscess:

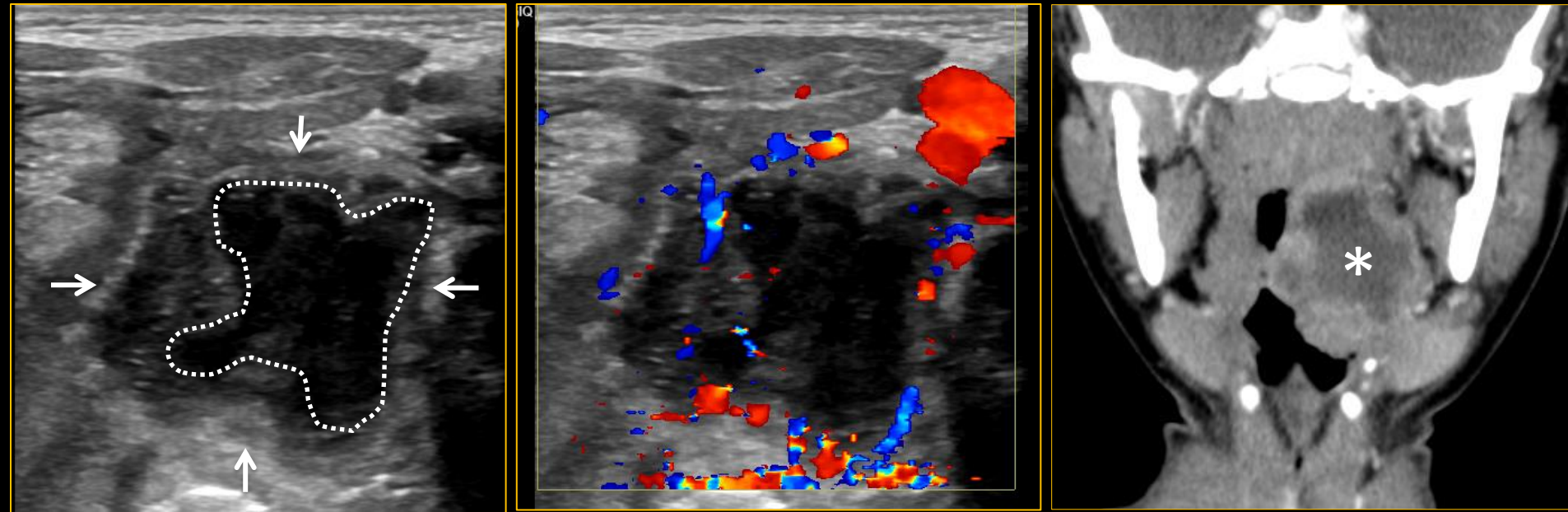


Intratonsillar Abscess:

- Discrete fluid pocket
- Surrounding parenchyma
- Responds well to antibiotics

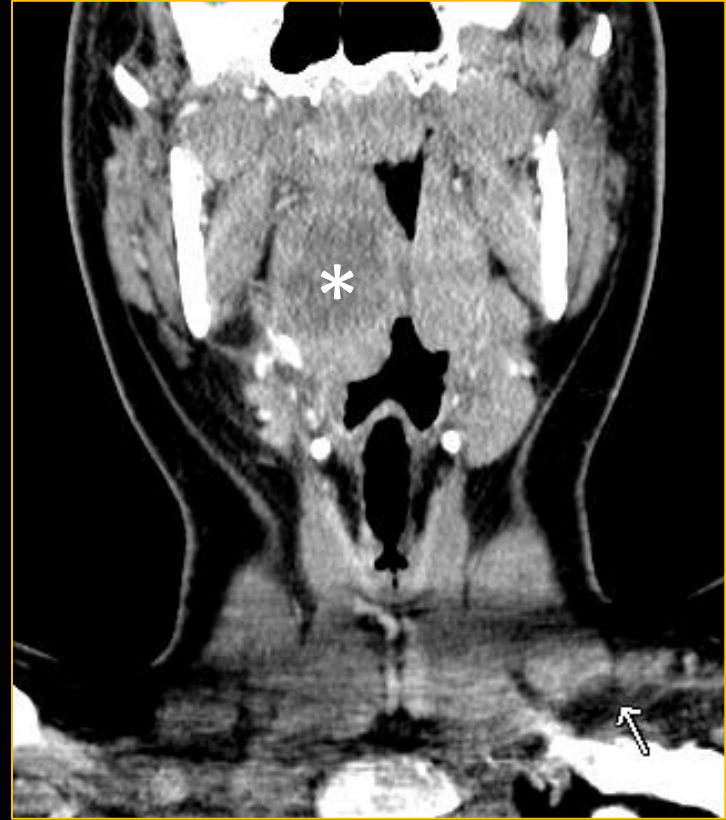
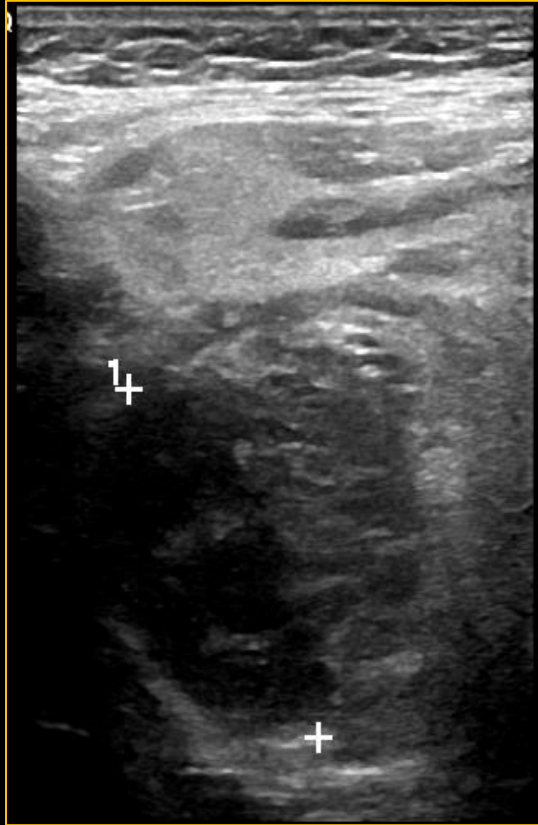
Peritonsillar Abscess:

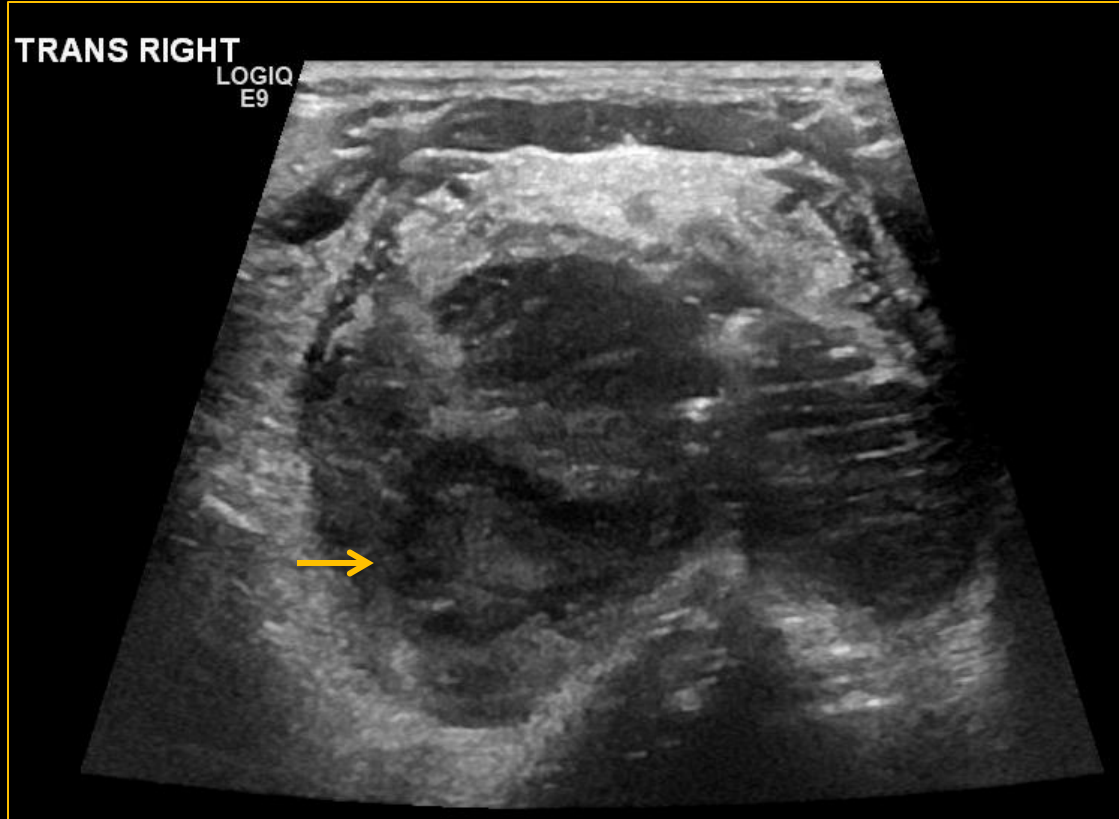


- Well-defined fluid collection
- Posterolateral to tonsil

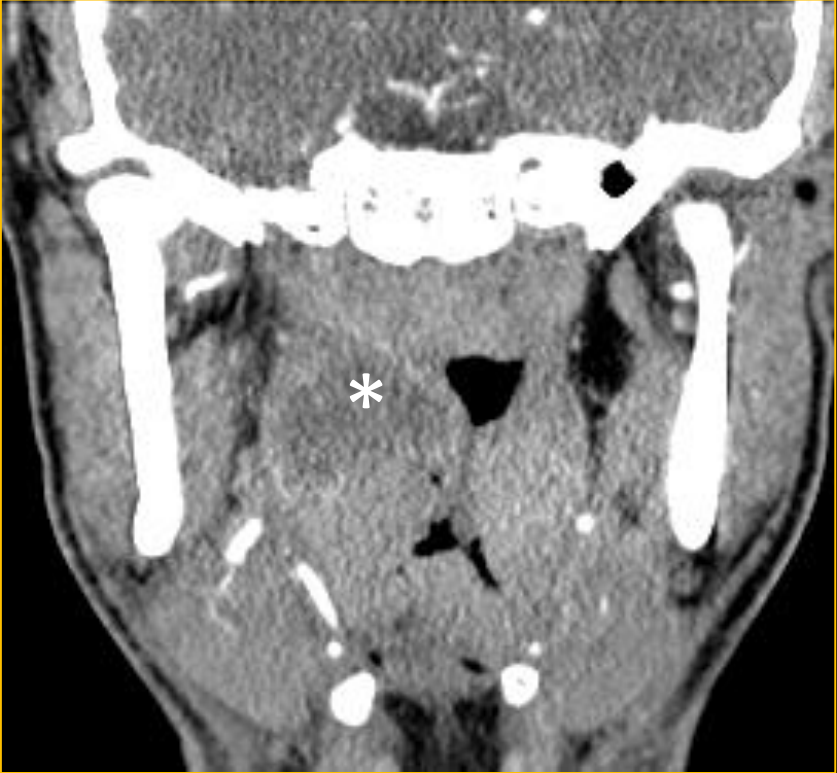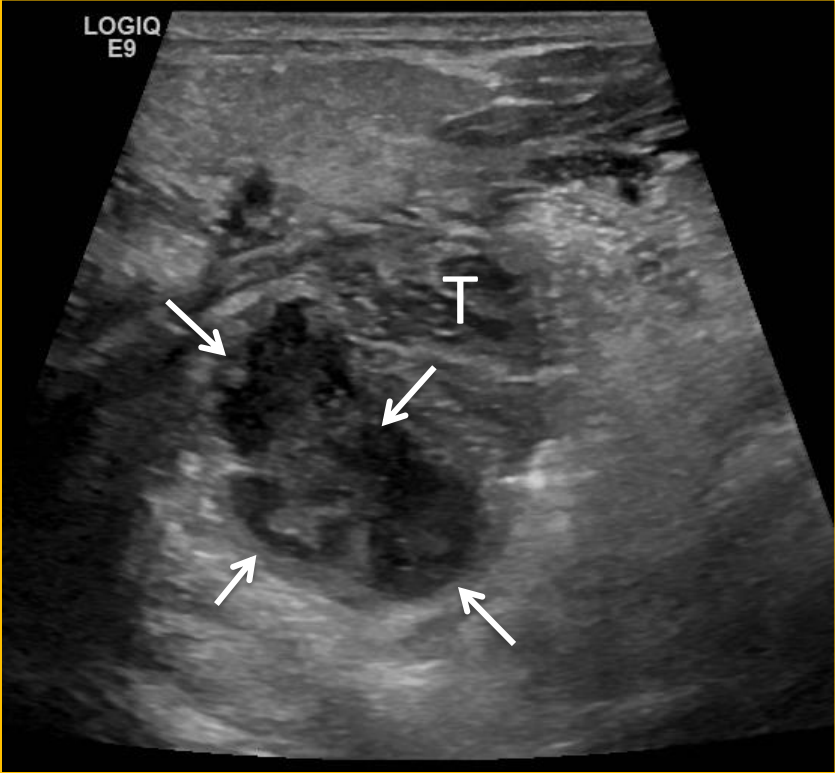
Peritonsillar Abscess:



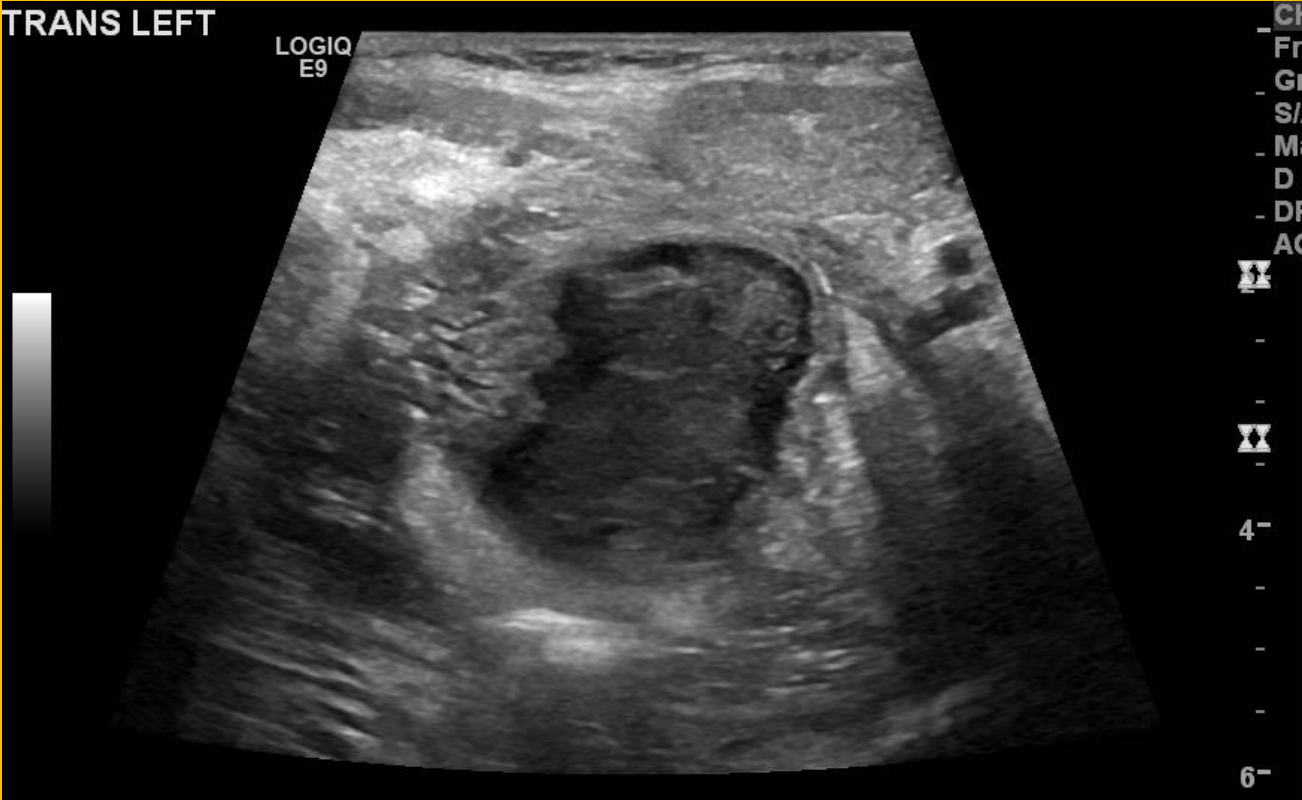Peritonsillar Abscess:



Peritonsillar Abscess:

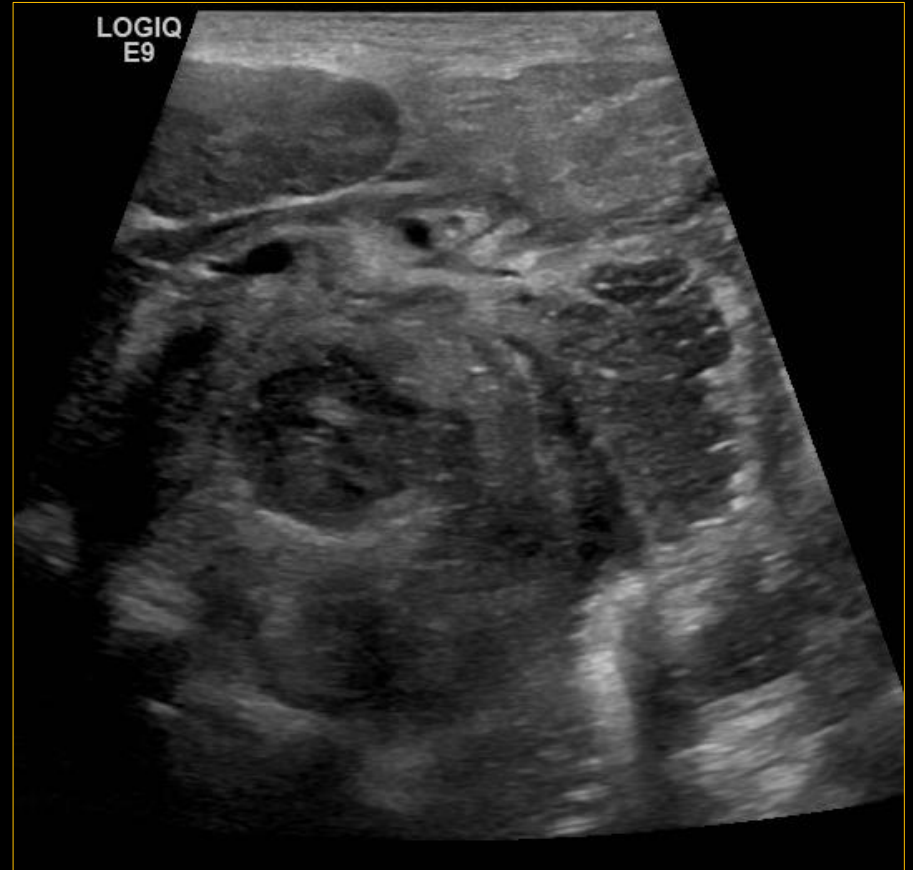

Peritonsillar Abscess:

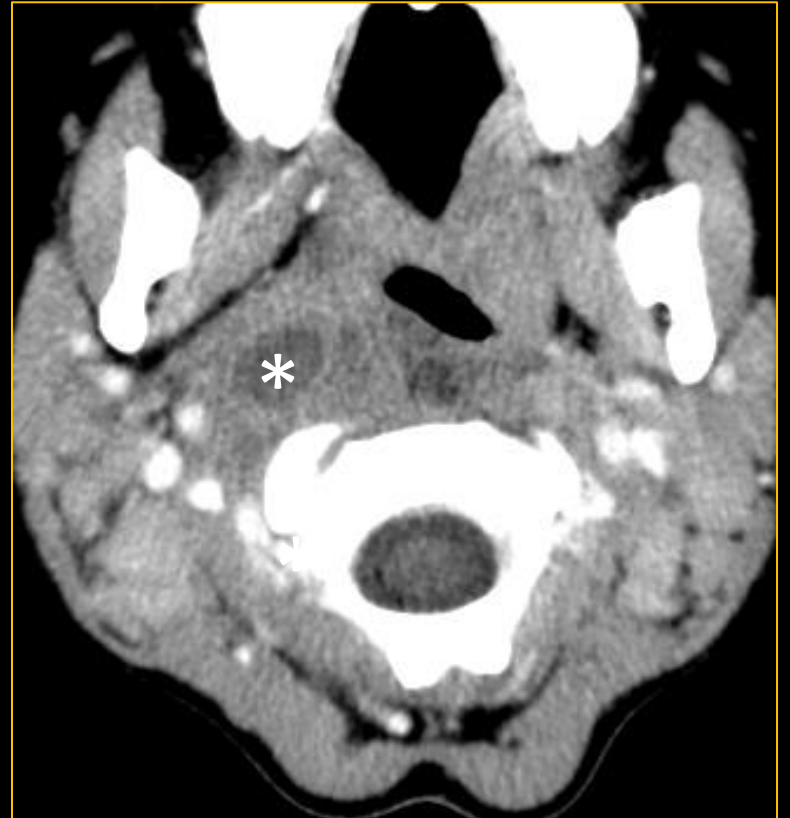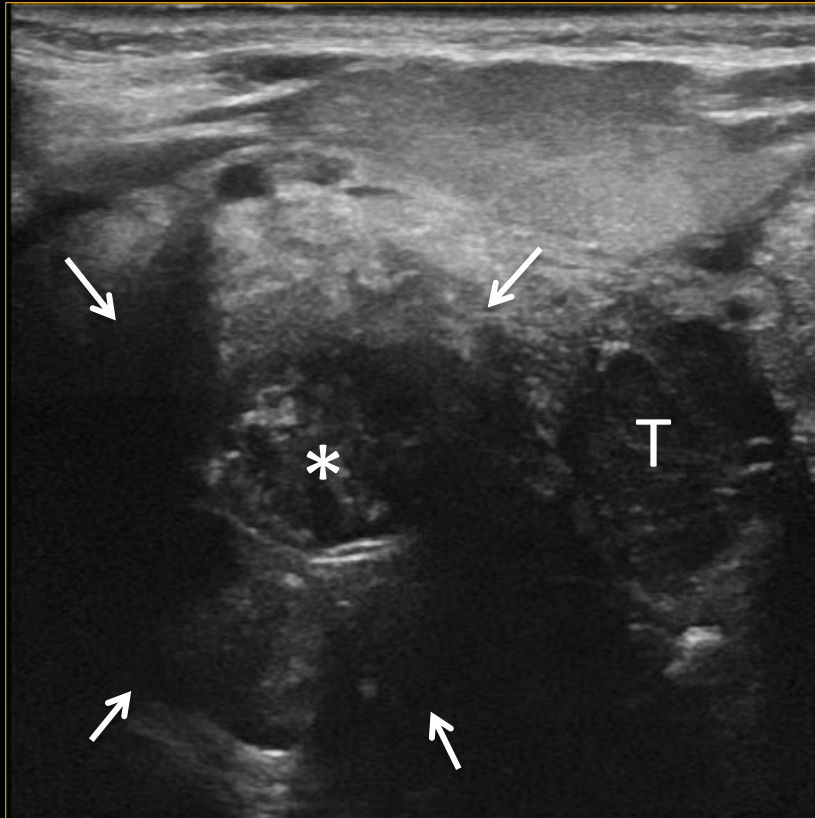


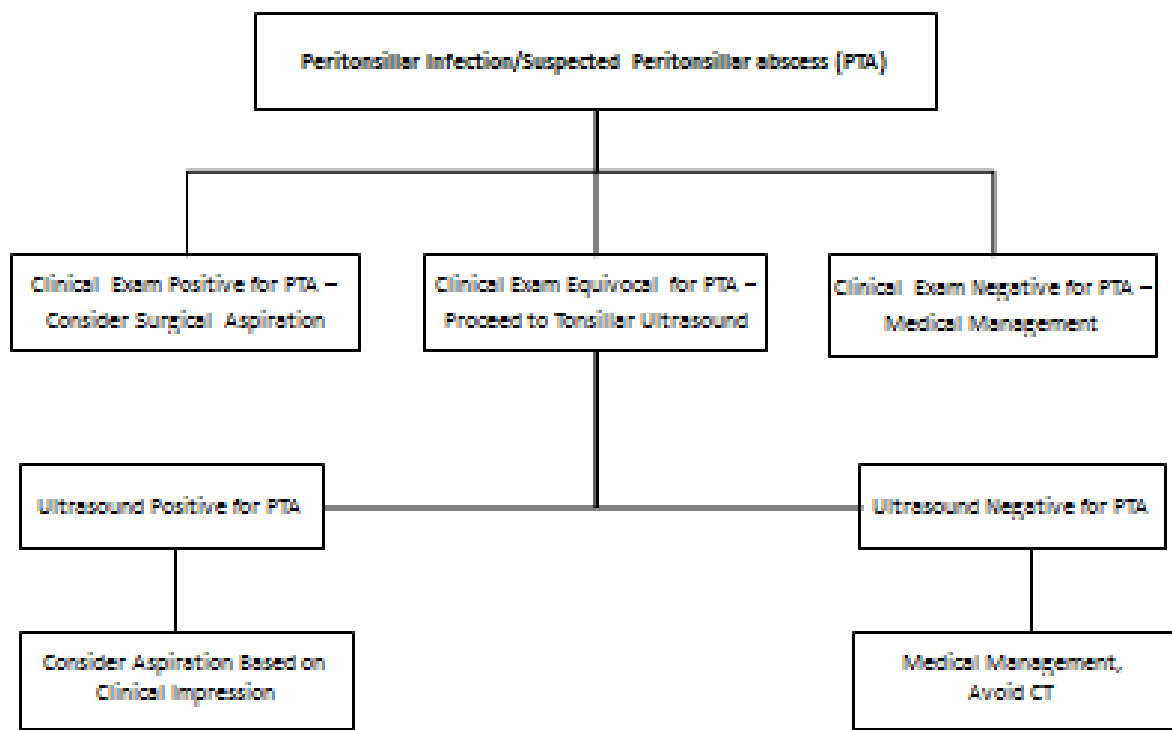
Parapharyngeal Abscess:

- Inflammation deep to tonsil
- Tonsil separate/uninvolved
- CECT is often helpful



Parapharyngeal Abscess:





Take Home Points – Tonsil US:

1. An ideal diagnostic tool for evaluation of tonsils in children
2. Quick, noninvasive, painless, cost-effective, easily available, no radiation or sedation
3. Reliably differentiates PTA from other tonsillar infections
4. Plays a critical role in identifying patients **who will not need surgical intervention.**

Thank you

abandark@childrensnational.org

anjumnb@gmail.com