

---

# **Ankle Ultrasound Tendons and Ligaments**

Monica Kalume Brigido, MD  
Michigan Medicine, Ann Arbor- MI

# Outline

---

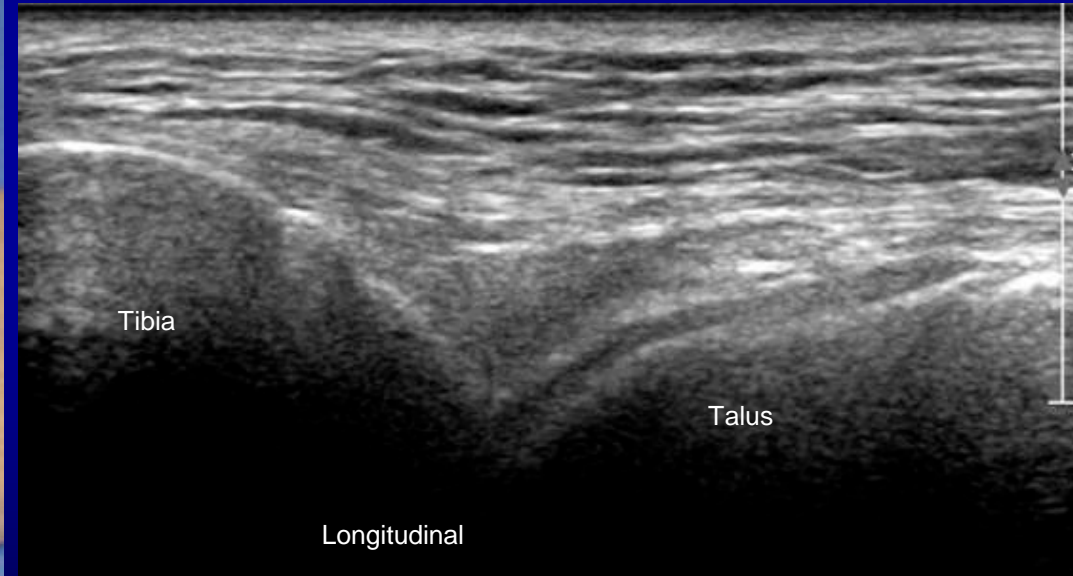
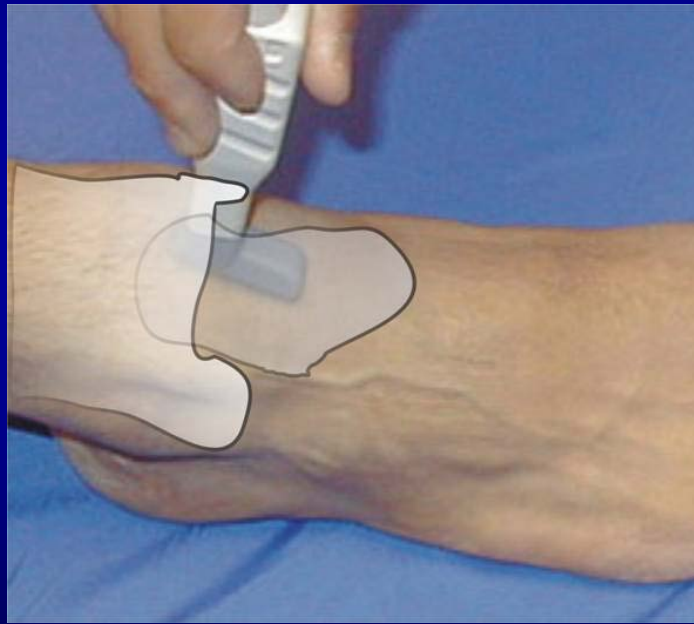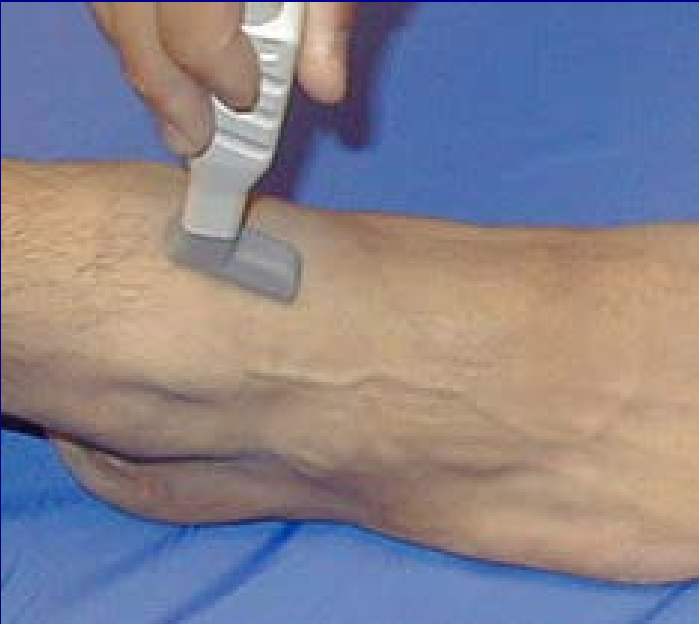- Ankle tendons and ligaments
- Ultrasound technique and normal ultrasound appearance
- Cases
- Live Demonstration: Complete ankle evaluation

# Ankle Ultrasound

Transducer: 10-15 MHz linear

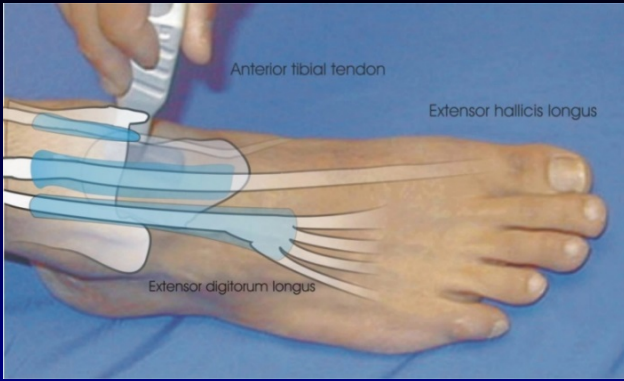
Systematic approach

Plantar Flexion - transducer in sagittal plane

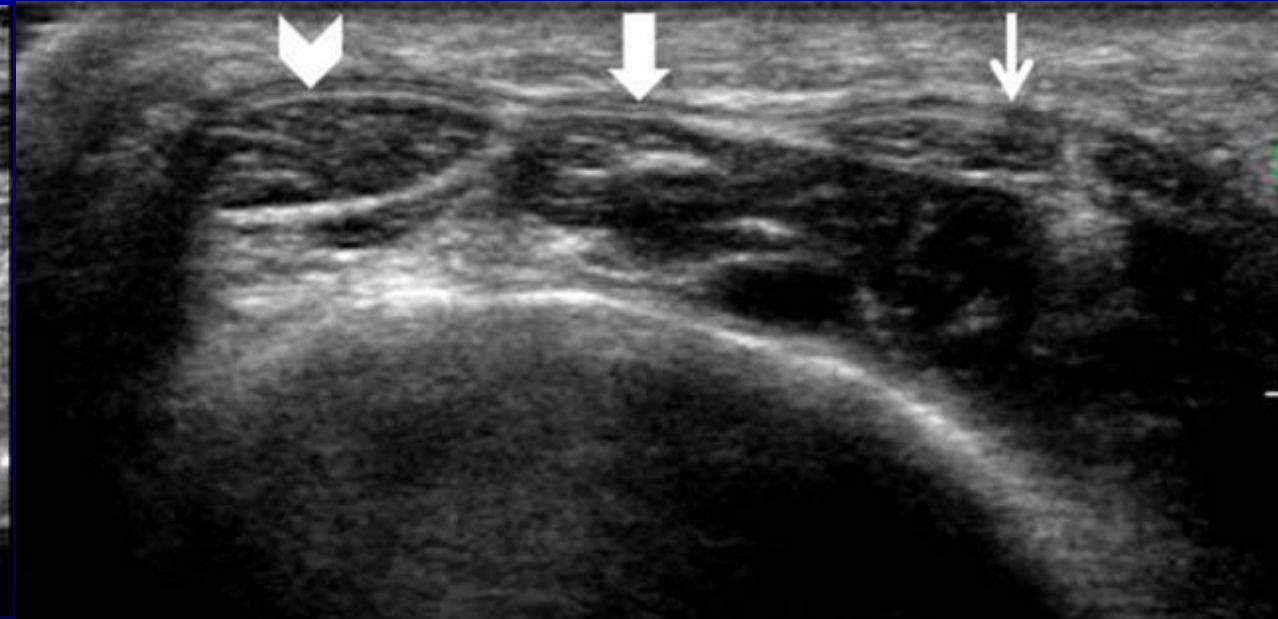
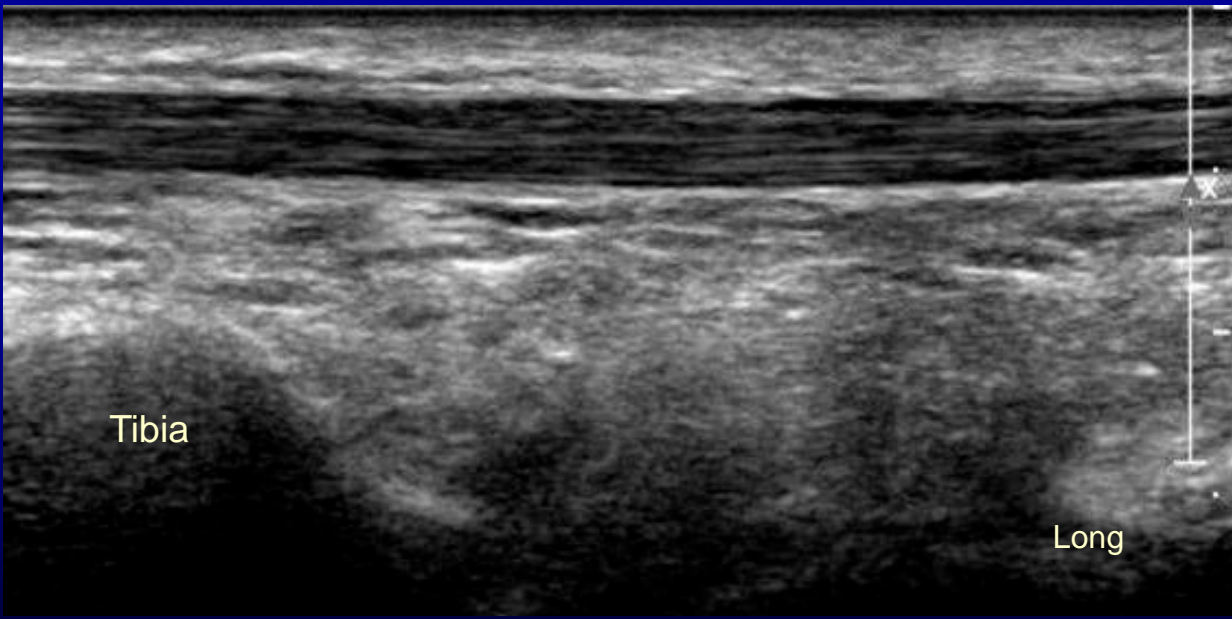


- Fad Pad – hyperechoic
- Hyaline cartilage - hypoechoic

# Anterior Ankle Tendons

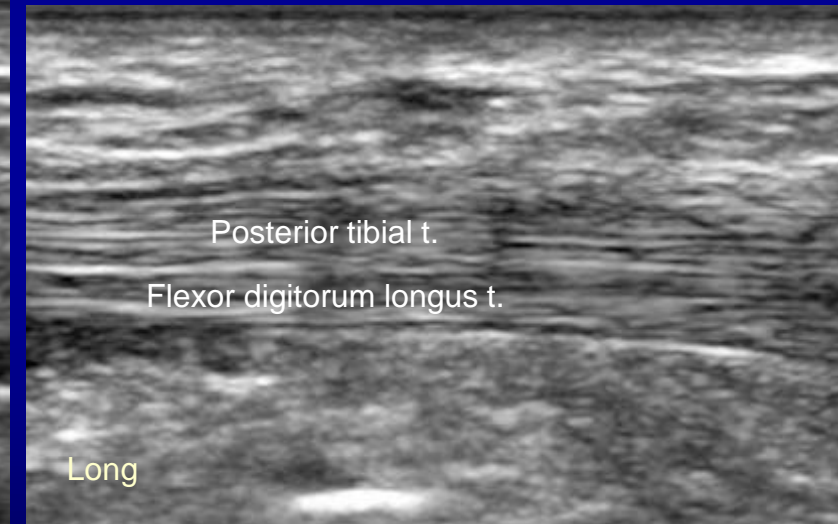
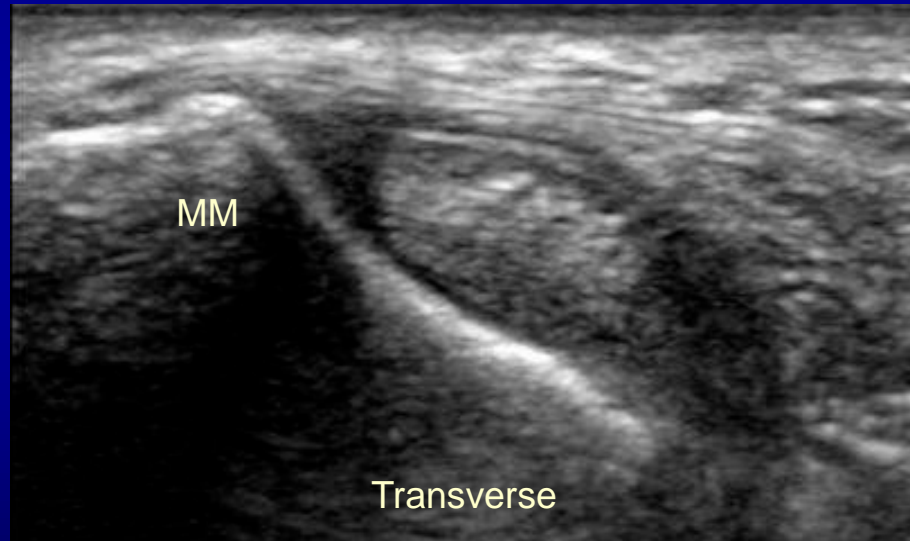
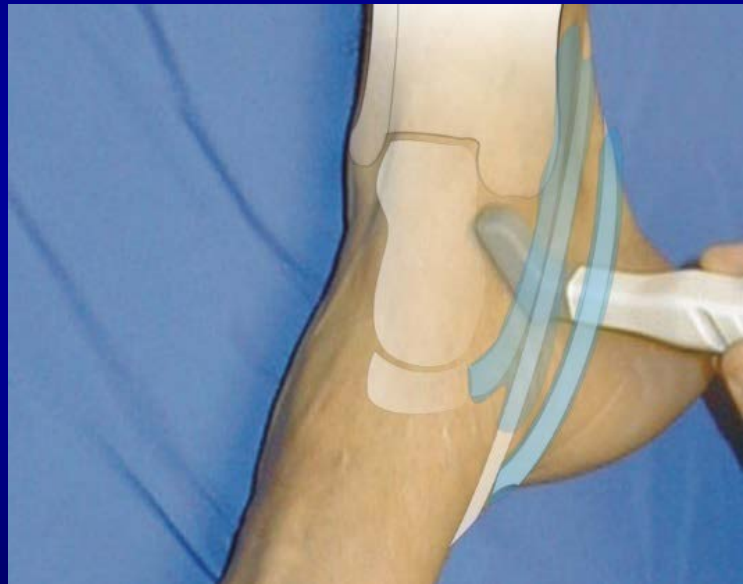
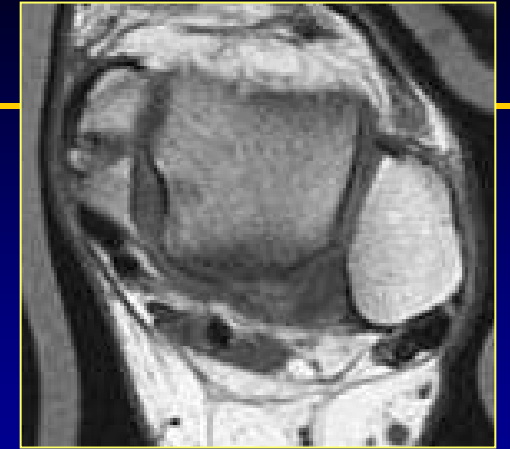
- Anterior Tibialis
- Extensor Hallucis Longus
- Extensor Digitorum Longus
- Extensor Retinaculum




# Medial Ankle Tendons

- Bone Landmark: Medial malleolus
- Normal Tendon: Fibrillar and hyperechoic



# Medial Ankle Tendons

---

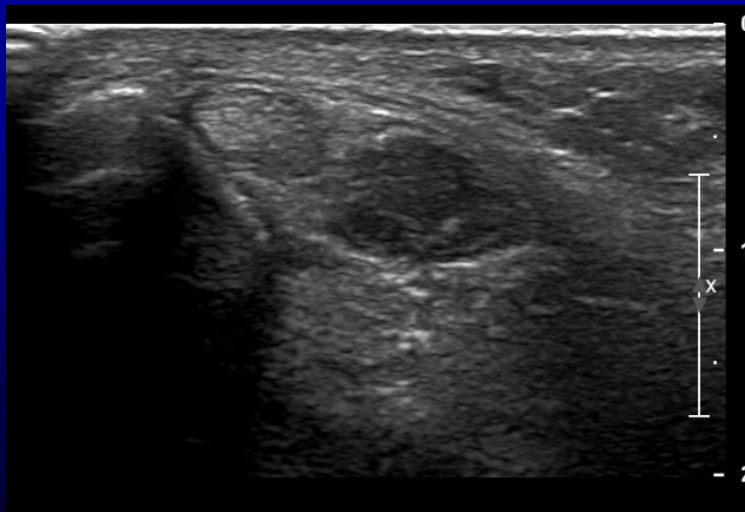
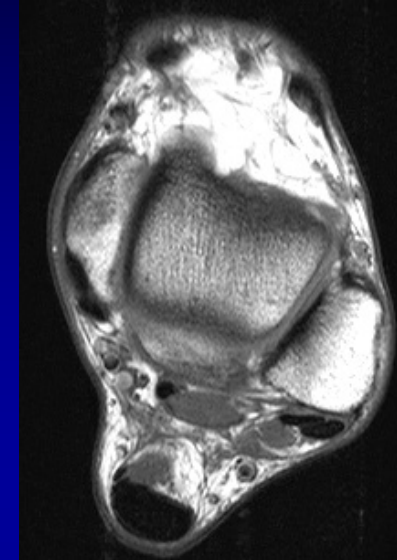
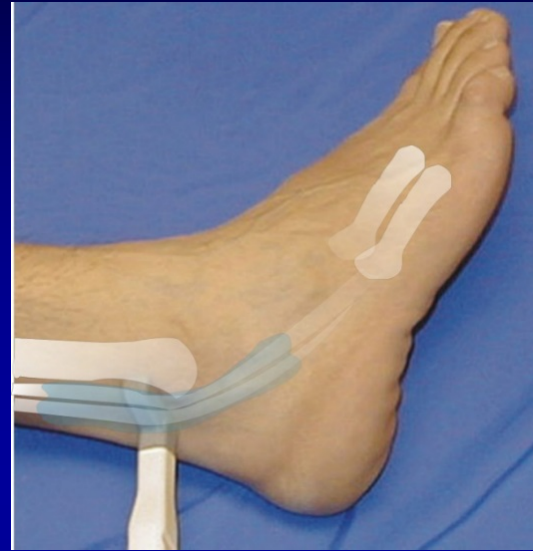

Dynamic


The tendons and the neurovascular bundle run through the tarsal tunnel

# Lateral Ankle Tendons

- Bone Landmark: Lateral Malleolus
- Peroneus Longus and Brevis Tendons



Transverse

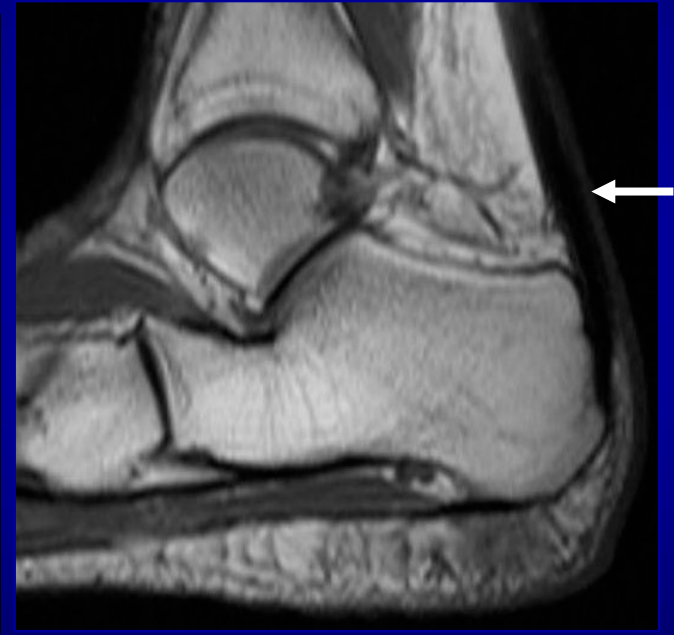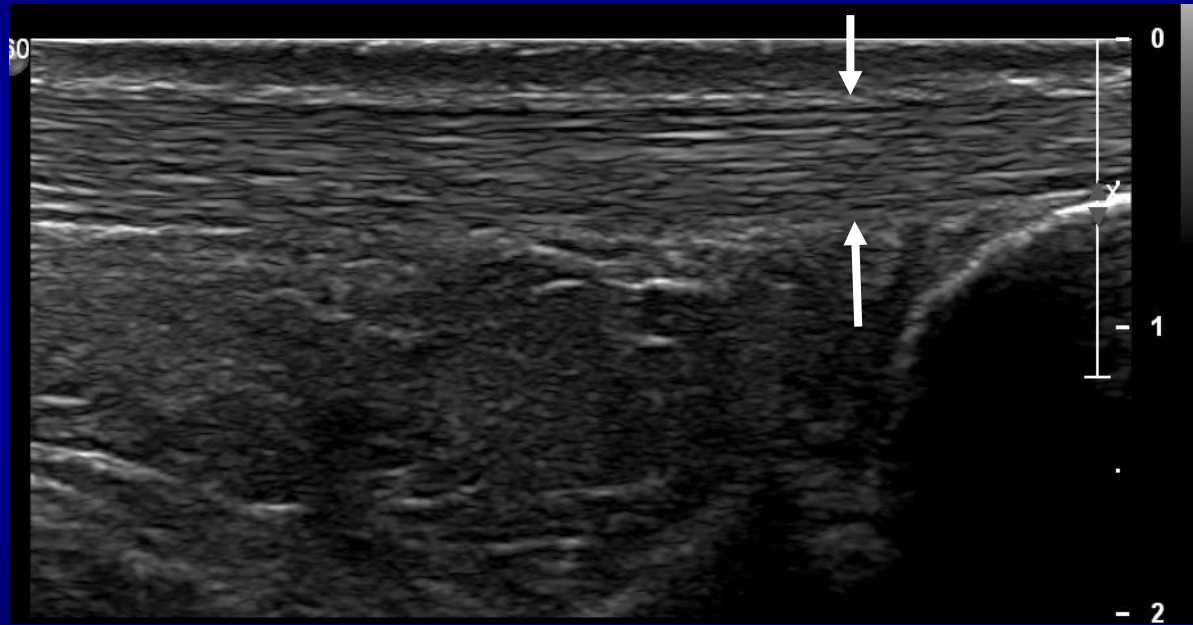

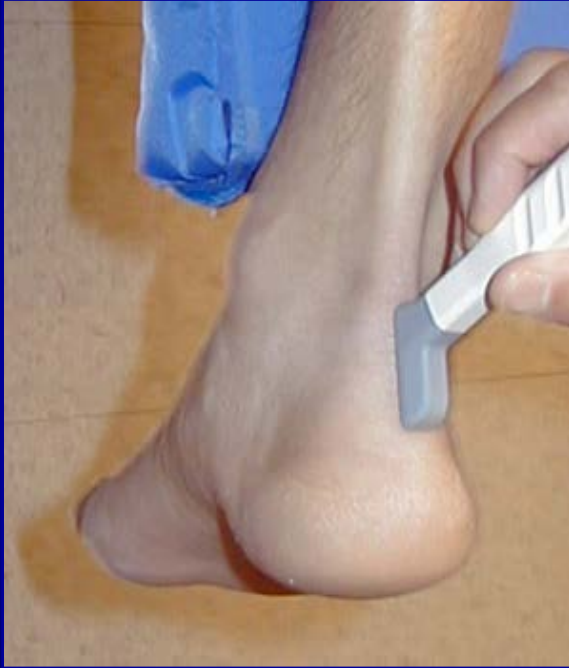
Dynamic



# Posterior Ankle

✓ Patient in prone position

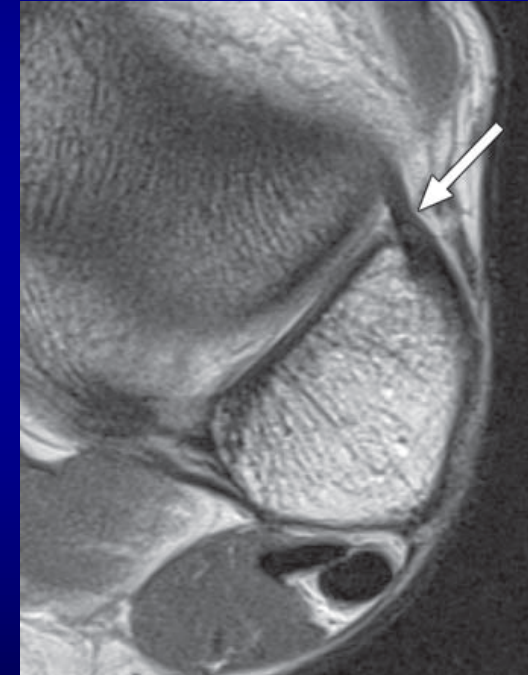
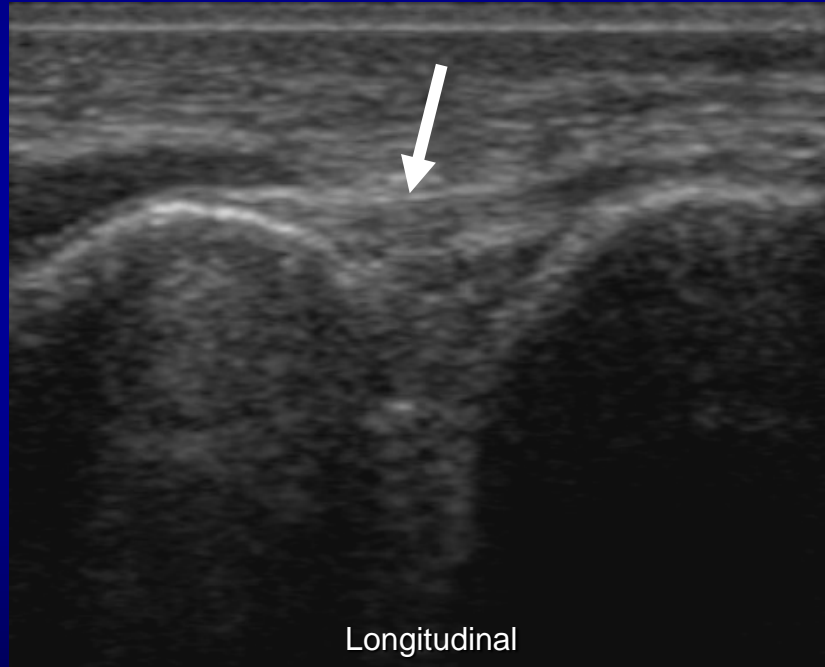
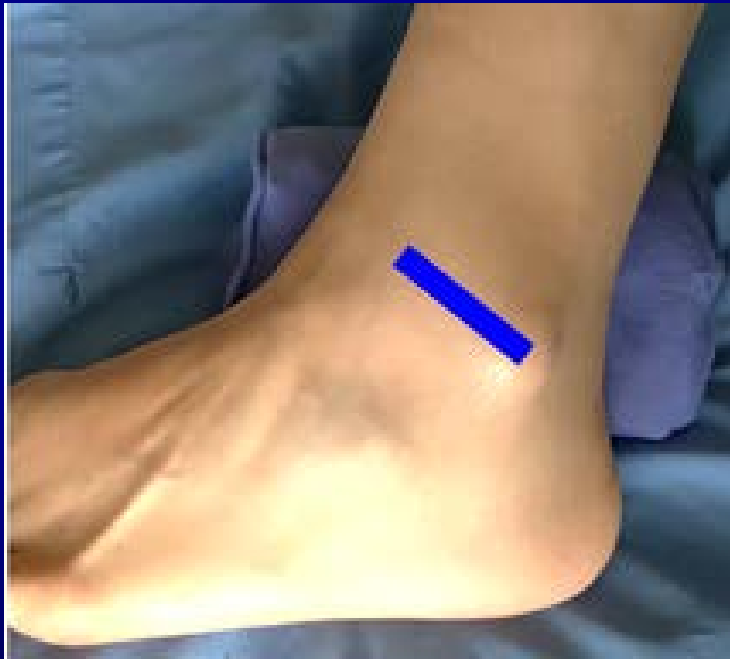

# Ankle Ligaments

## Anterior Tibiofibular Ligament

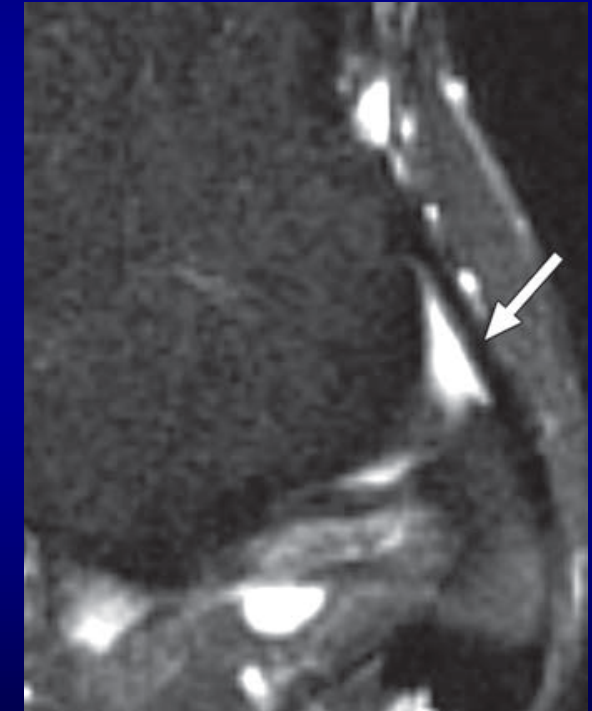
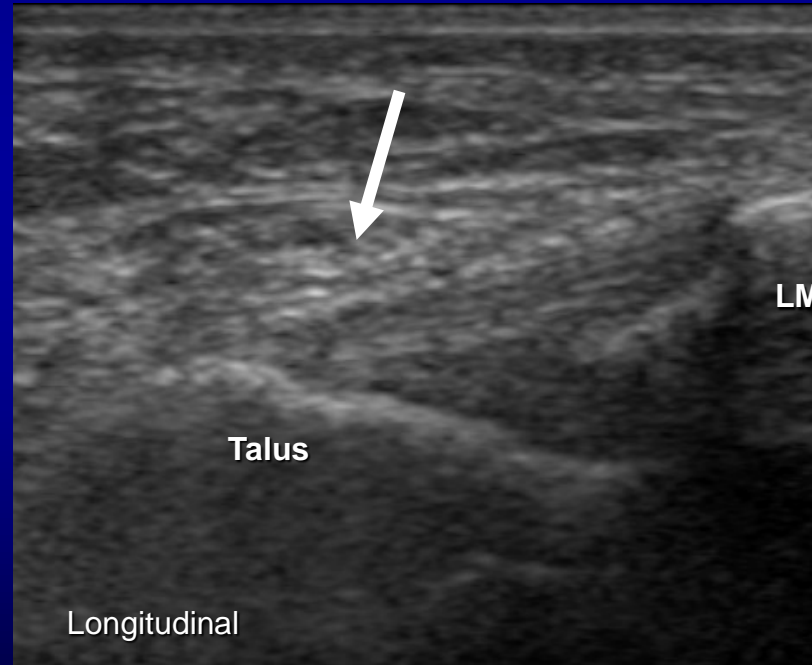
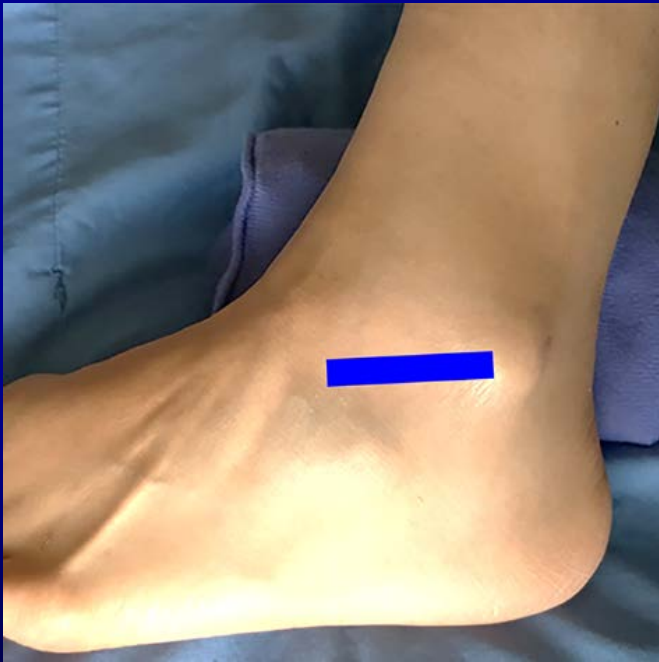
Injured in severe ankle sprain



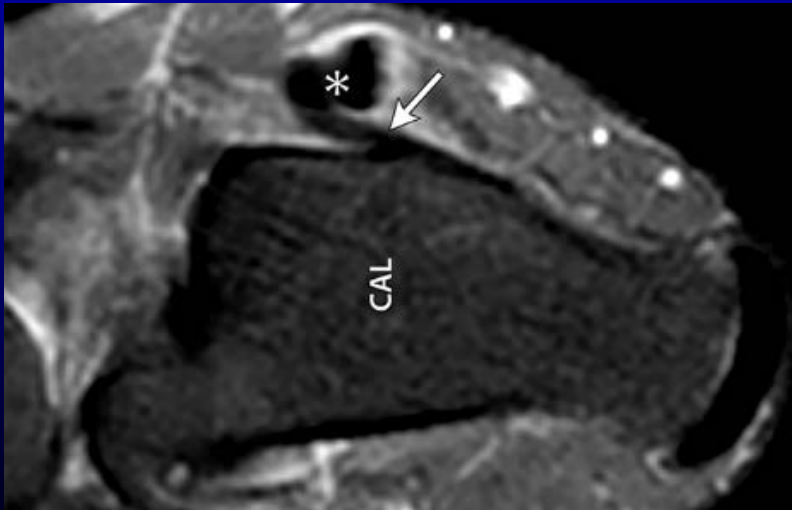
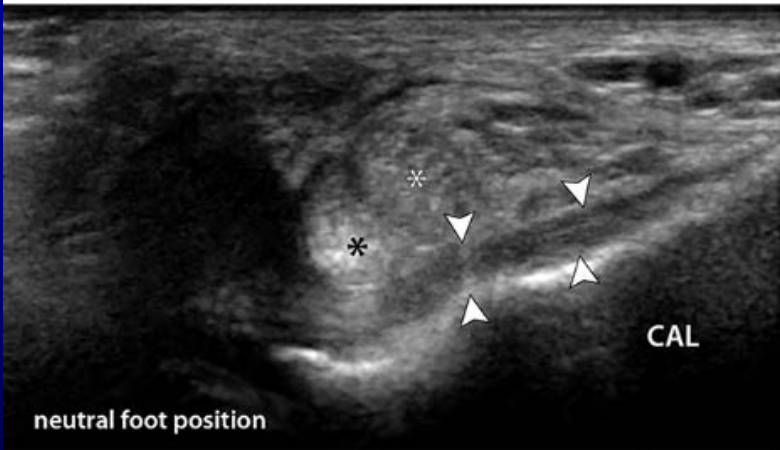
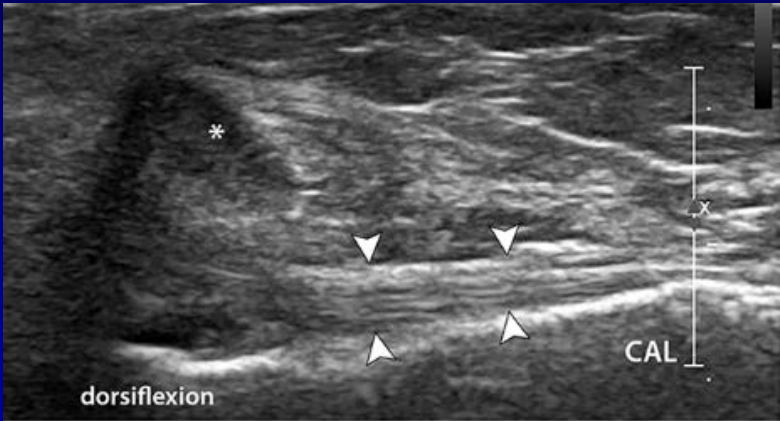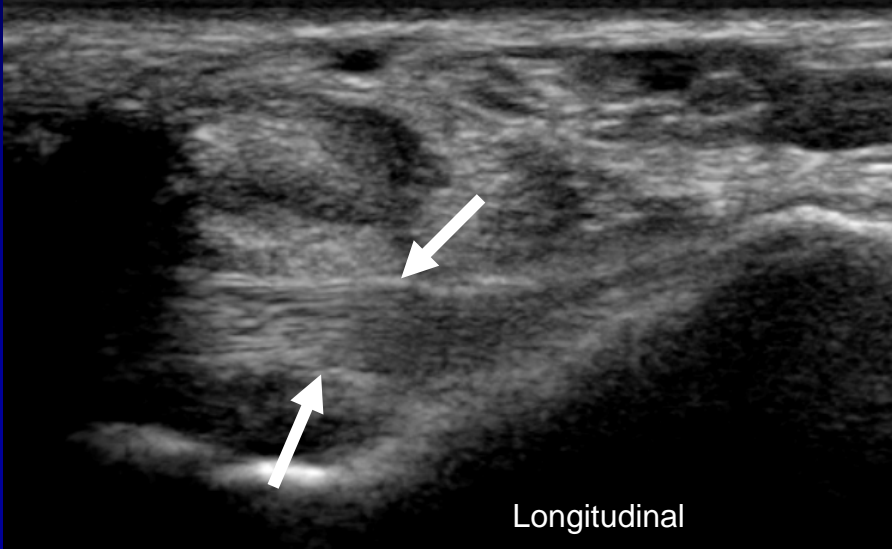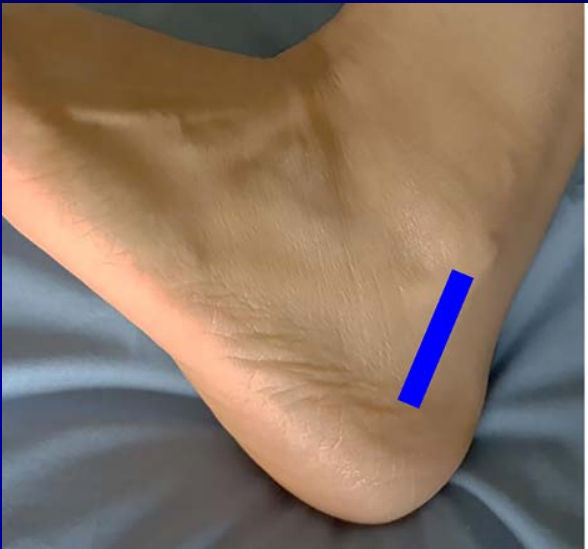
- Bone Landmark: Tib & Fib
- Normal ligament: Hyperechoic and fibrillar

# Ankle Ligaments

## Anterior Talofibular Ligament



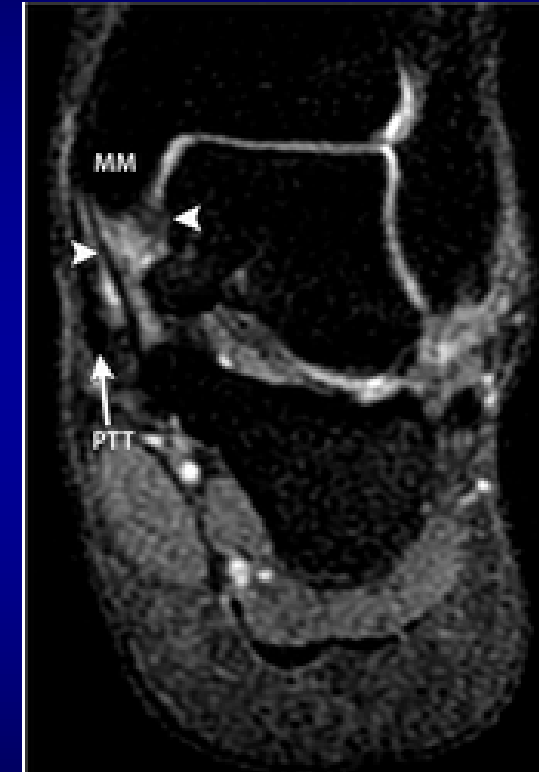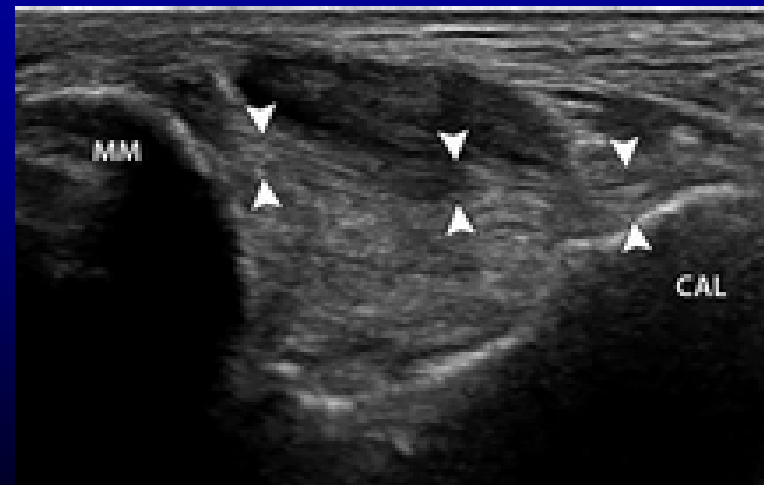
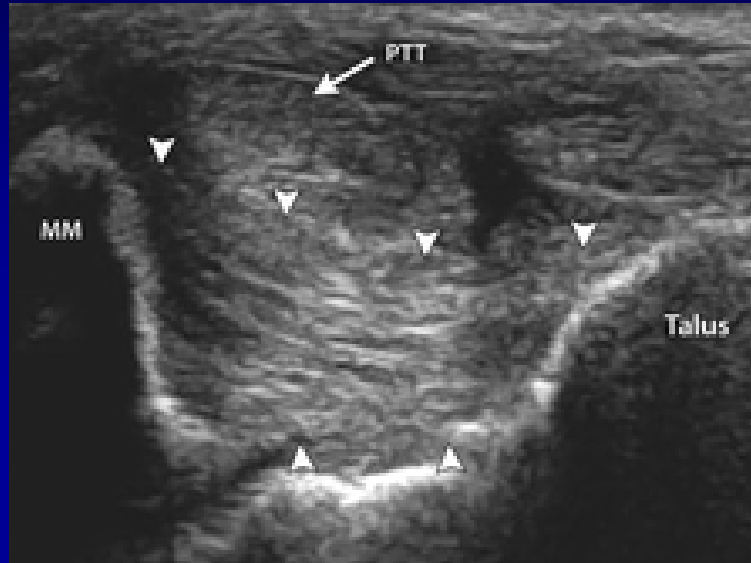
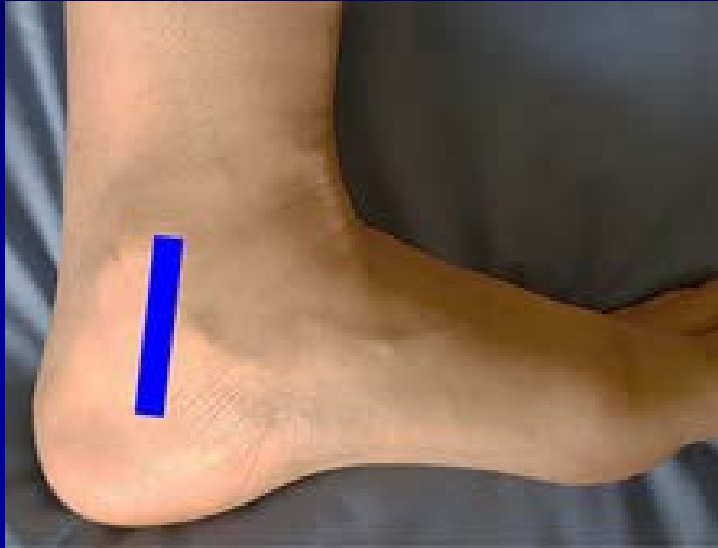# Calcaneofibular Ligament



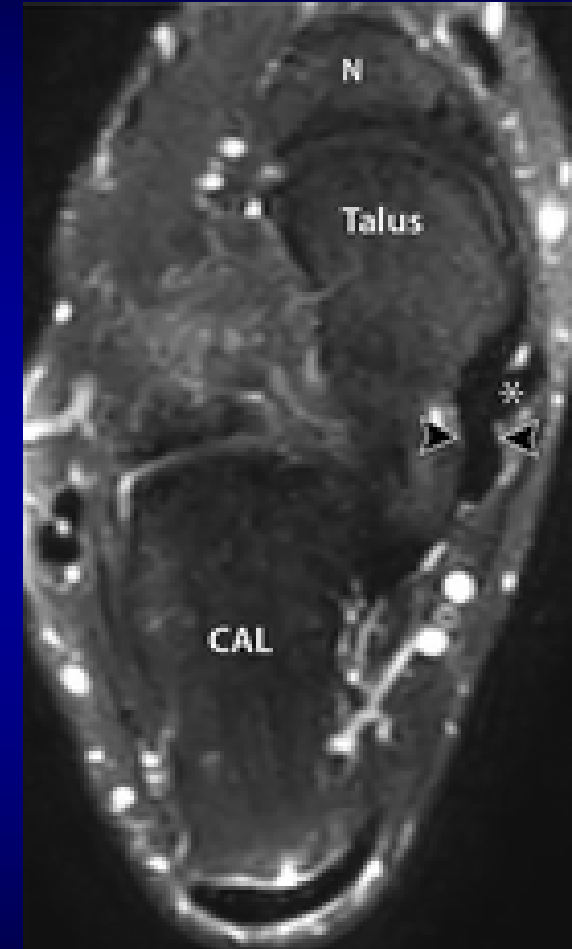
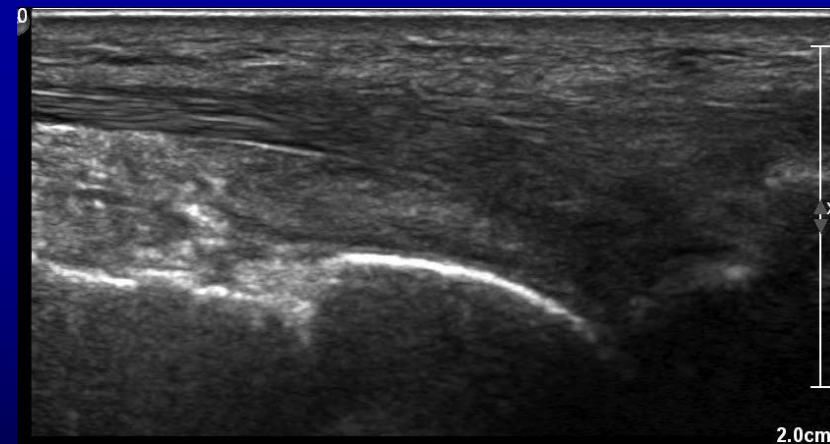
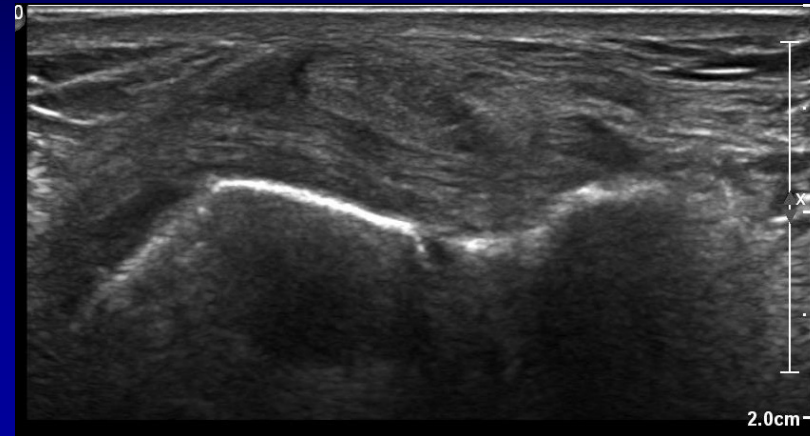
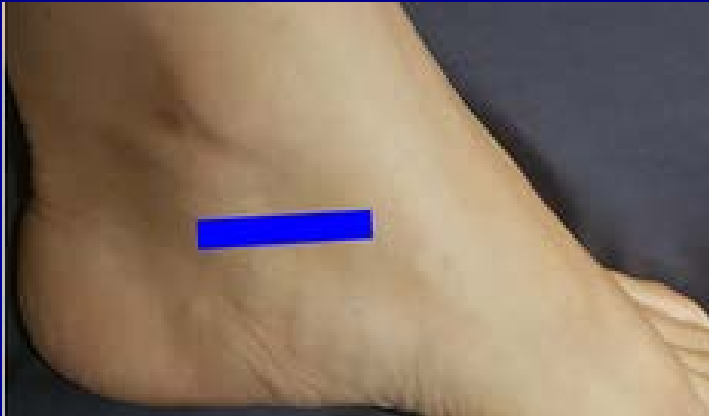Dorsiflexion improves visualization

JUM, Volume: 38, Issue: 2, Pages: 513-528, First published: 12 August 2018, DOI: (10.1002/jum.14716)

# Deltoid Ligament Complex

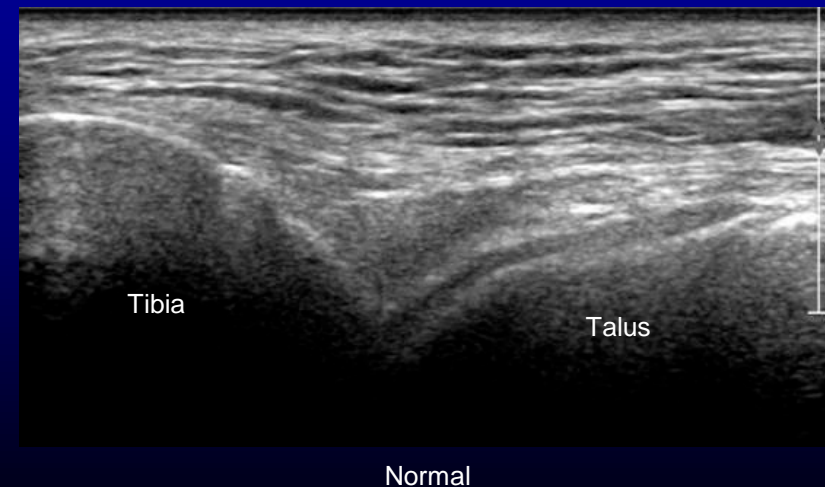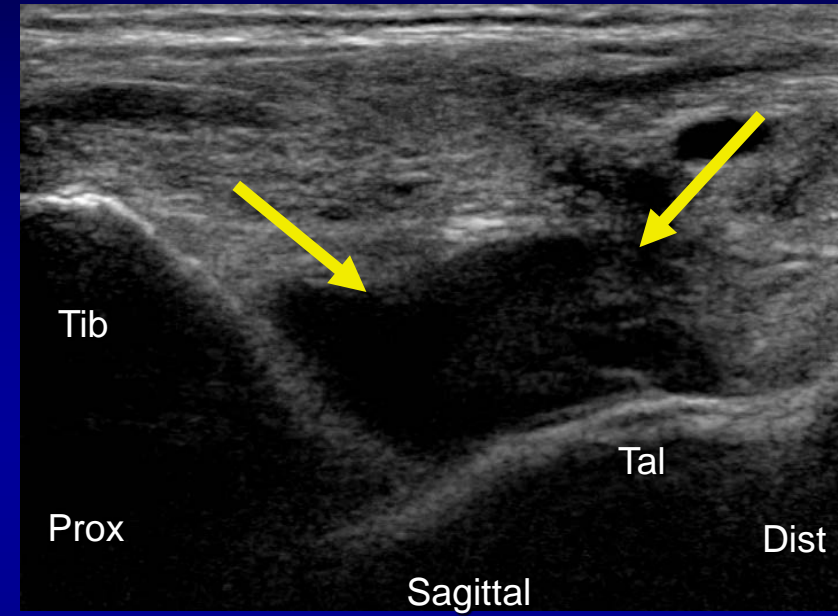


# Spring Ligament



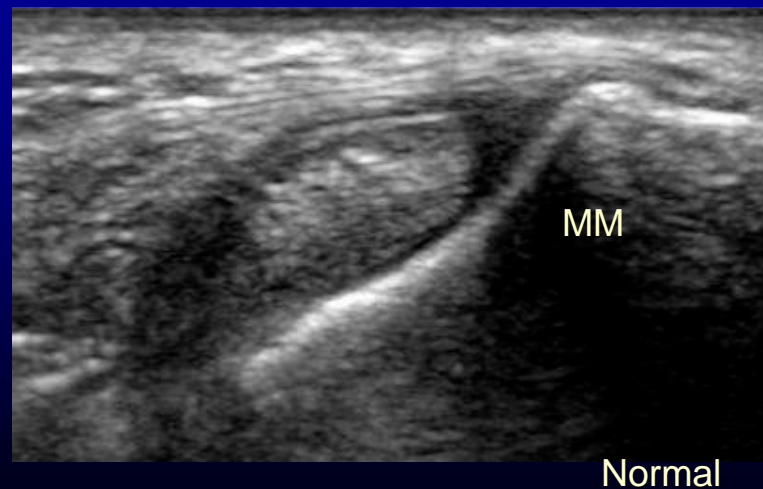
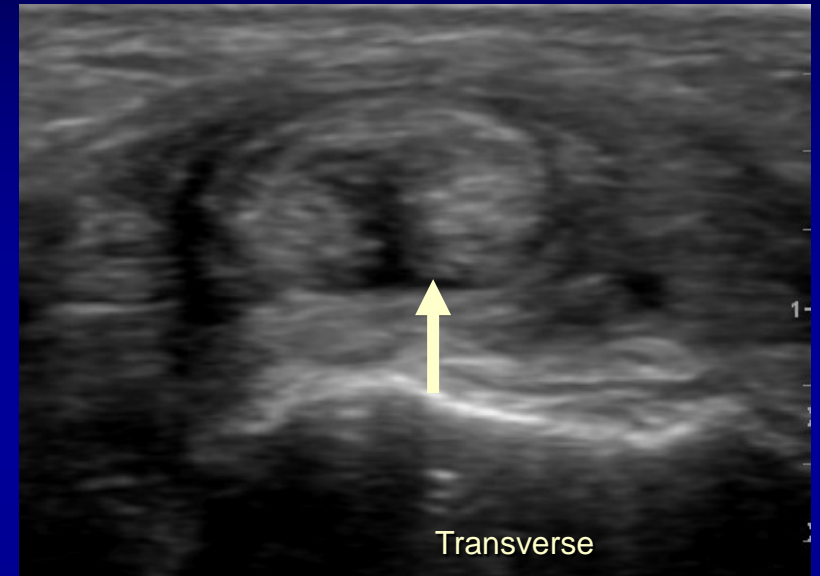
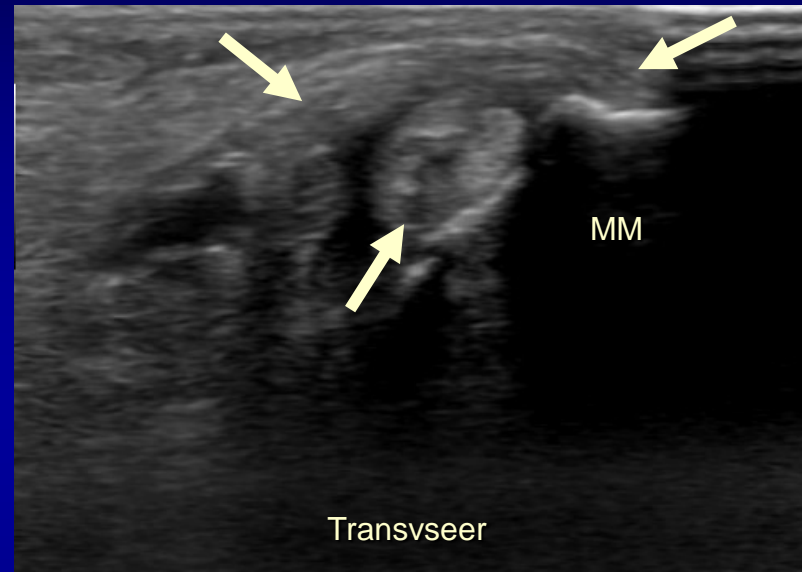
# Case # 1: Joint Effusion

- Best visualized: anterior joint recess
- Appearance:
  - Anterior fat pad displacement
    - Simple fluid - Anechoic
    - Complex fluid - Hypoechoic, internal echos



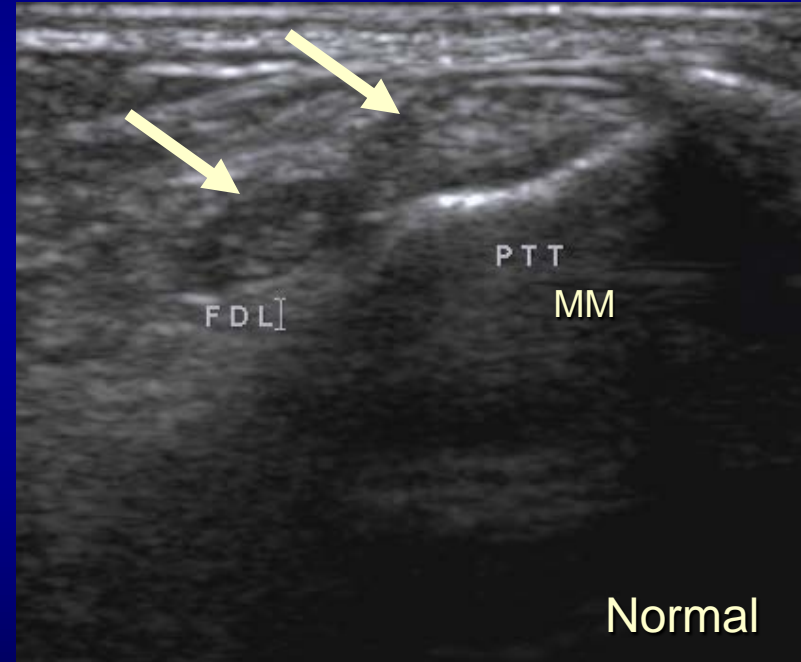

# Case # 2: Posterior Tibialis Tendon Longitudinal Split

- Site:
  - Just distal to medial malleolus
  - At insertion
- Medial retinaculum injury → Subluxation



# Case # 3: Posterior Tibialis Tendon Subluxation

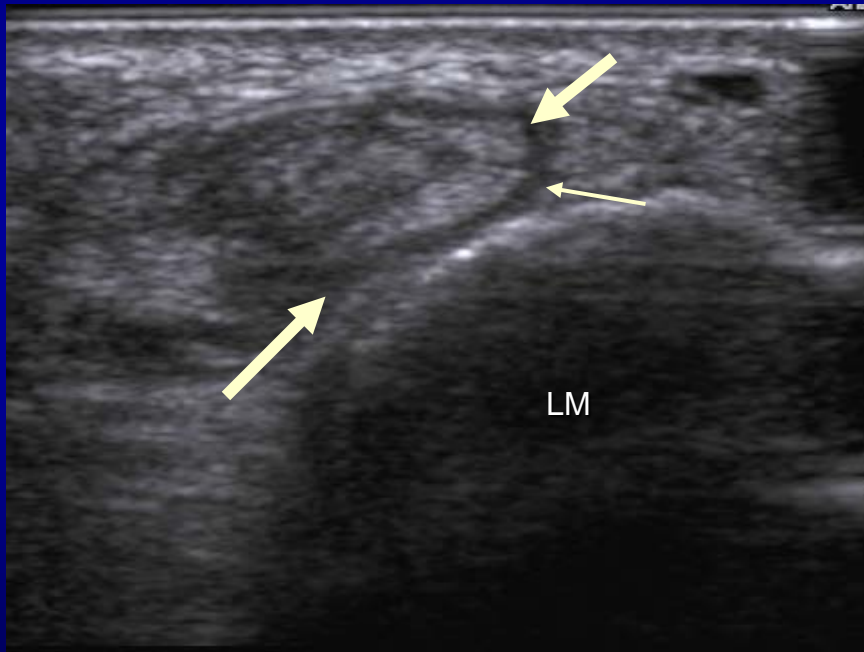---





# Case # 4: Peroneus Brevis Longitudinal Split

---

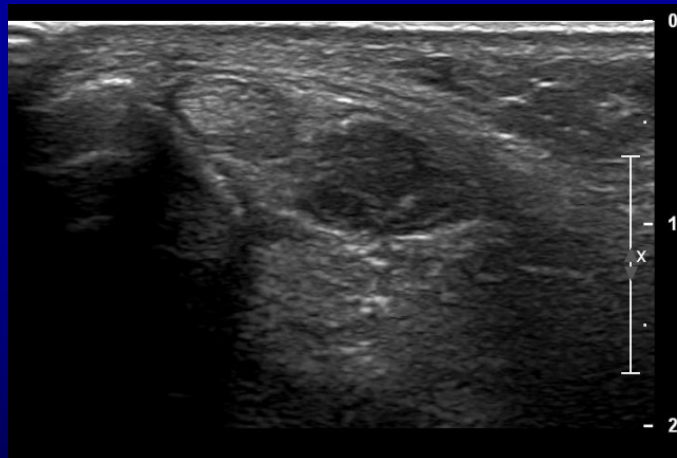


Transverse

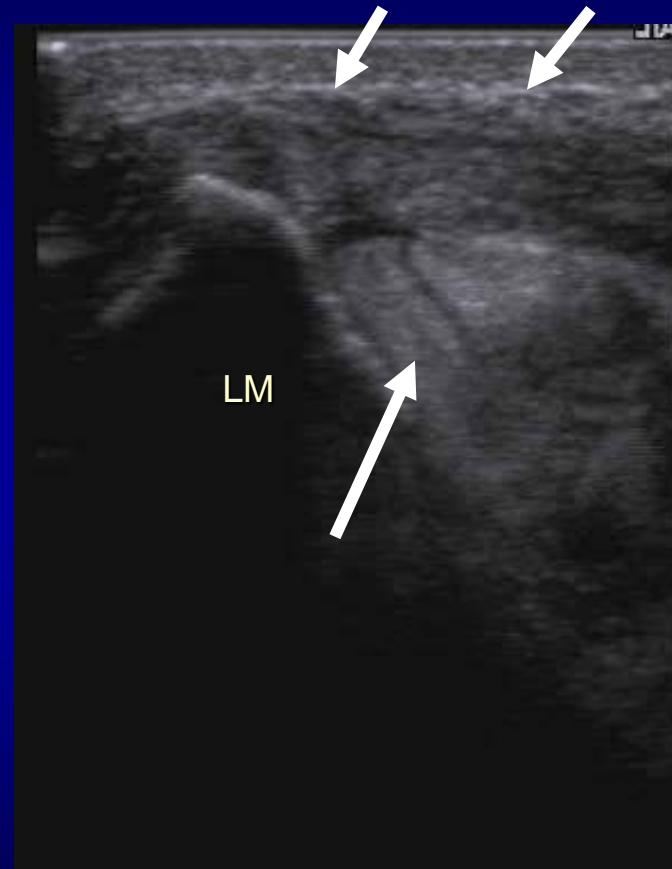

Dynamic


# Case # 5: Peroneus Brevis Subluxation Retinaculum Injury



Normal



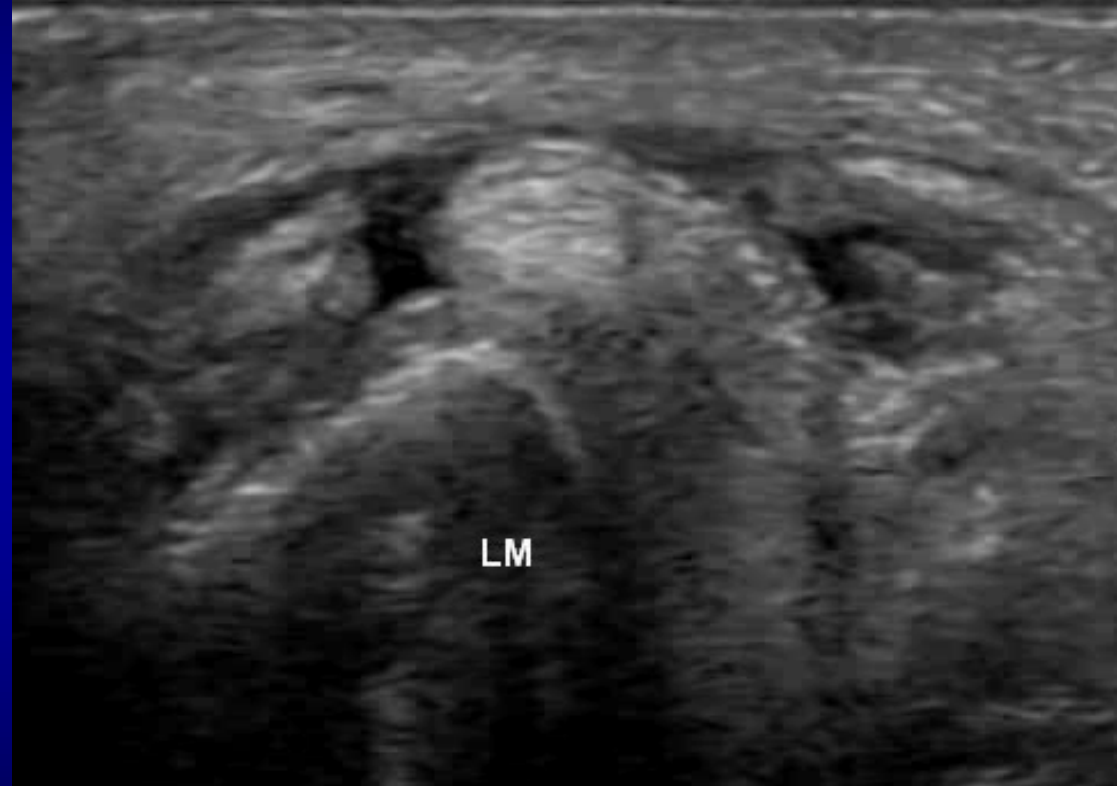
Transverse



Dynamic:  
Dorsiflexion and eversion

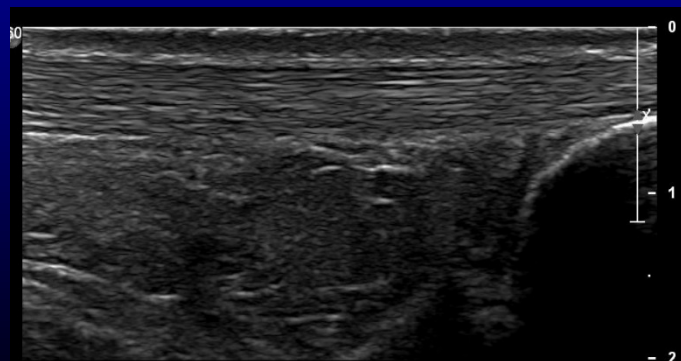
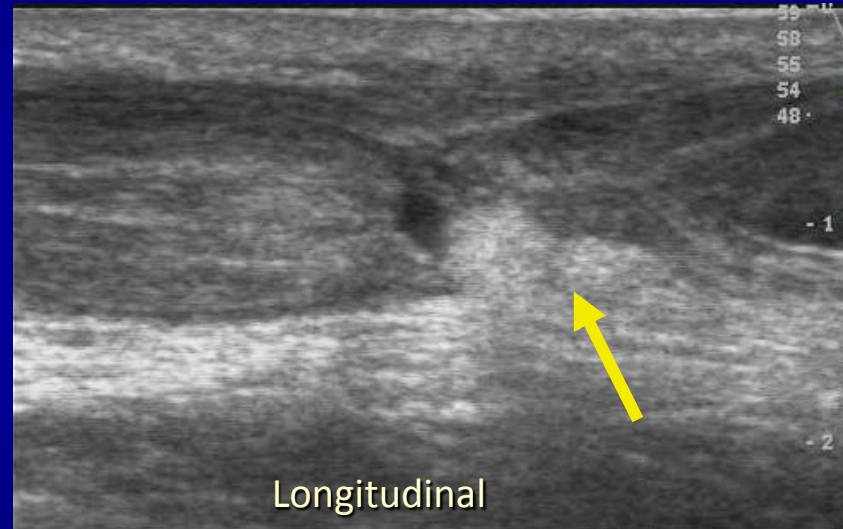
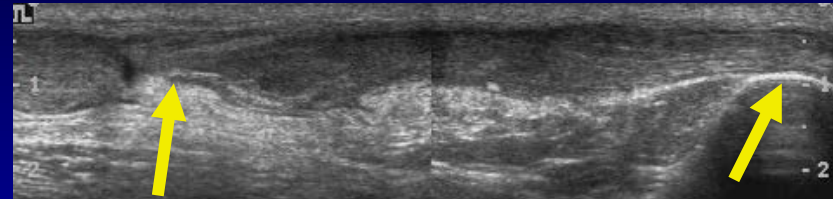
# Case # 7: Dislocating Peroneal Tendon

---



# Case # 8: Achilles Tendon Complete Tear

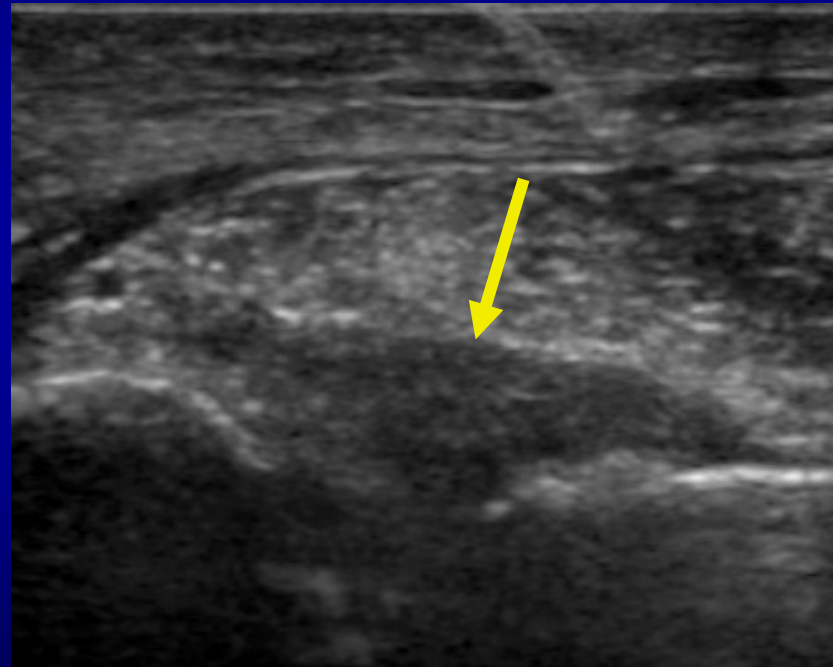
- Appearance:
  - Discontinuity of fibers
  - Herniation of fat pad into the defect
  - Posterior shadowing at the tendon ends
- Dynamic evaluation: Plantar and dorsiflexion
  - Lack of normal movement
  - Gap measurement with # degrees of plantar flexion: if  $< 1$  cm – conservative treatment



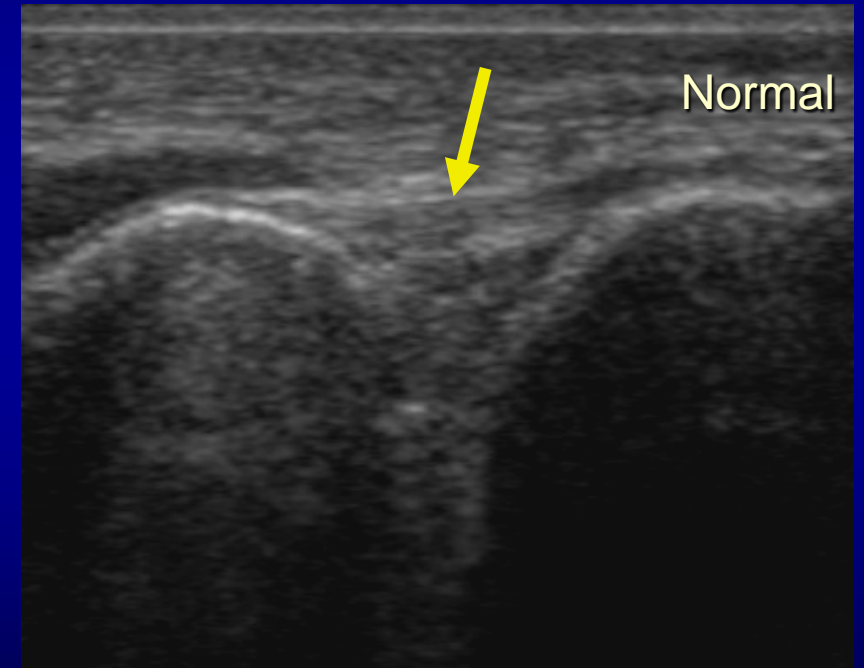
Dynamic  
( Plantar and dorsiflexion)

# Case # 9: Anterior Tibiofibular Ligament Tear

- US Appearance of lig. tear:
  - Loss of fibrillar echotexture
  - Thickening and hypoechogenicity
  - +/- Avulsed osseous fragment
  - Fluid through the defect → Acute tear

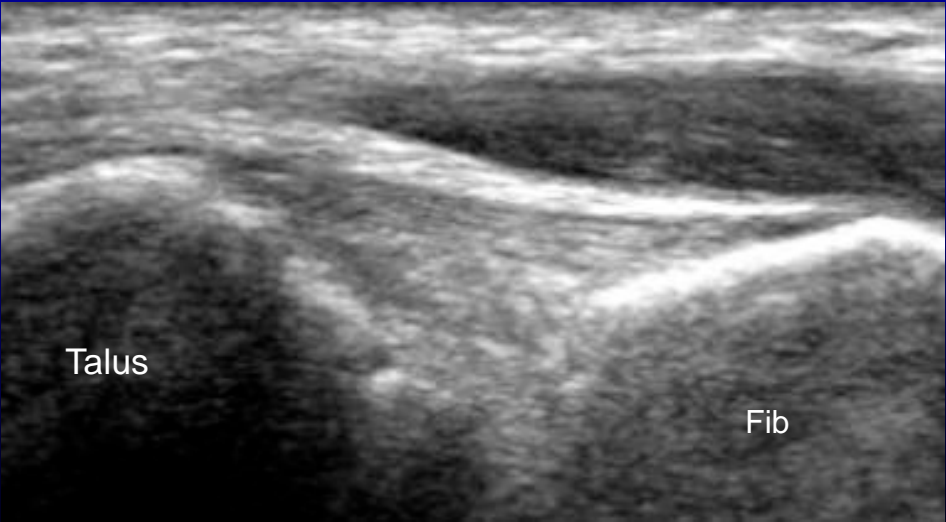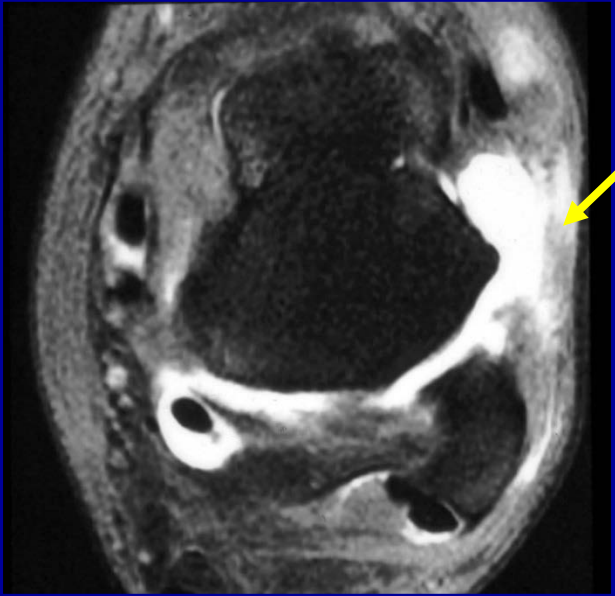
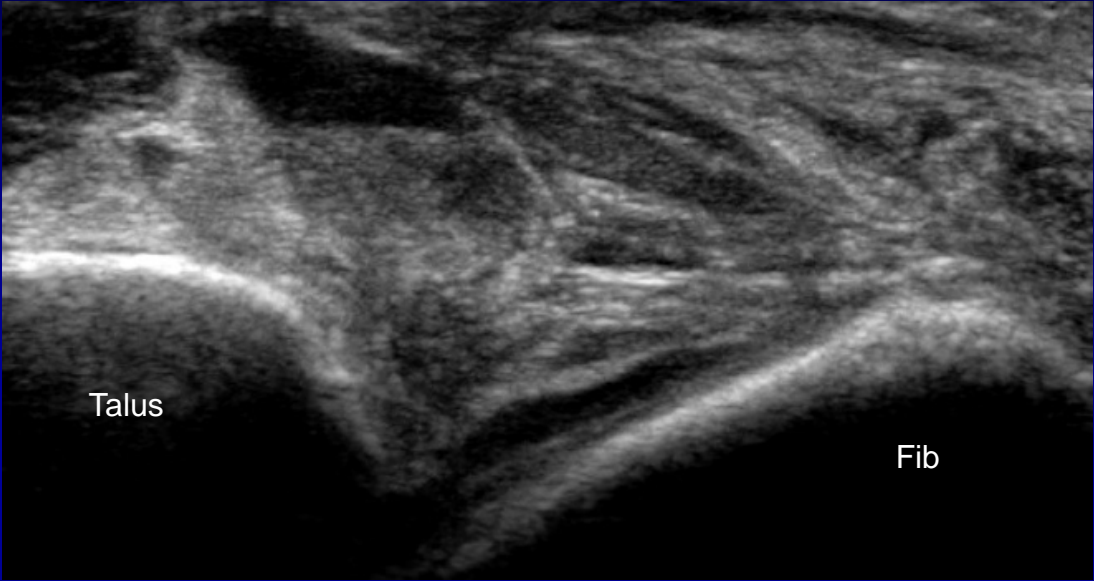


Longitudinal



Longitudinal

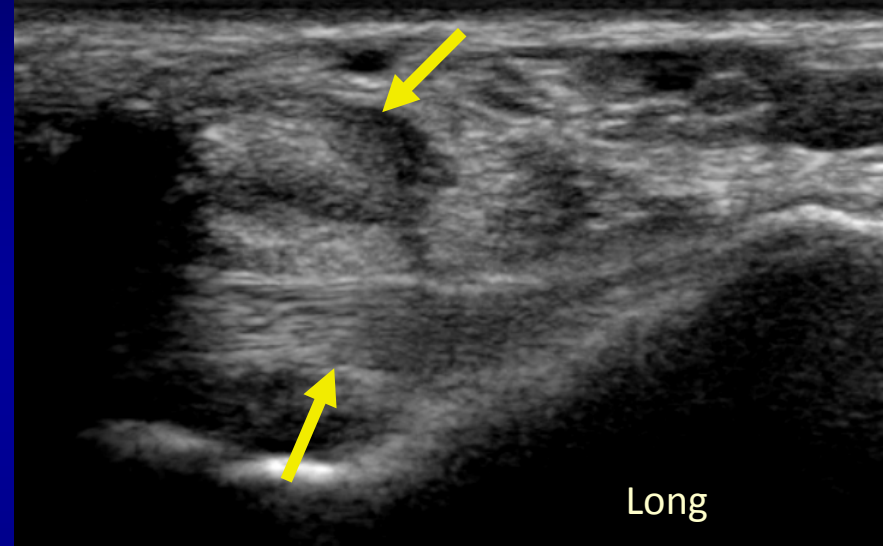
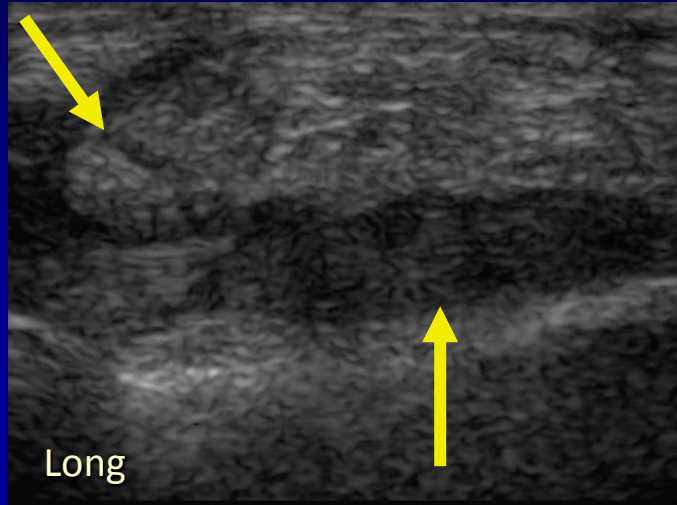
# Case # 10: Anterior Talofibular Ligament Tear



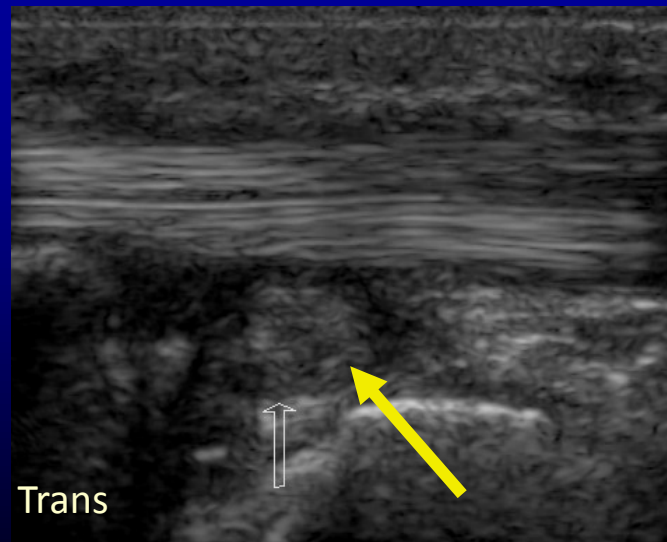
Normal

# Case # 11: Calcaneofibular Ligament Tear

---

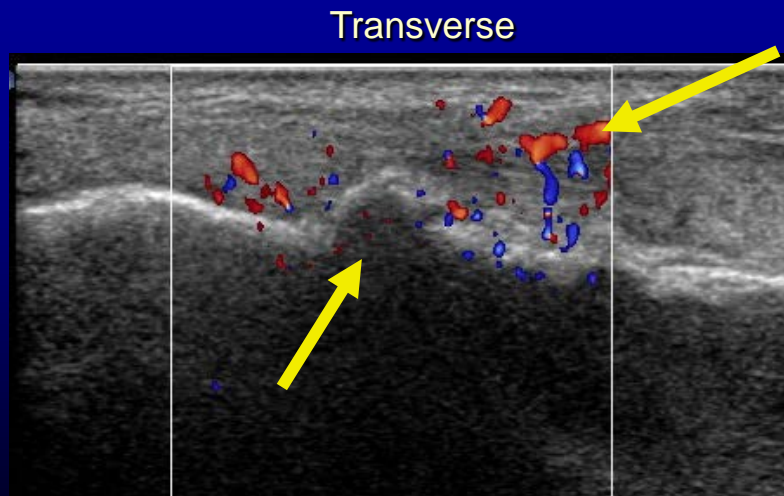
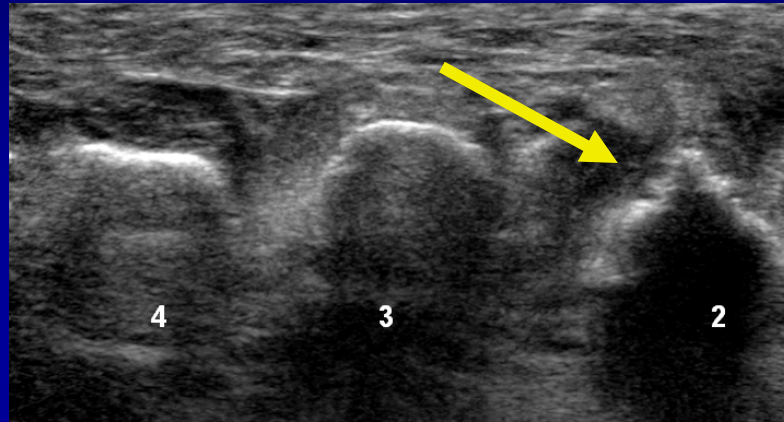


Normal

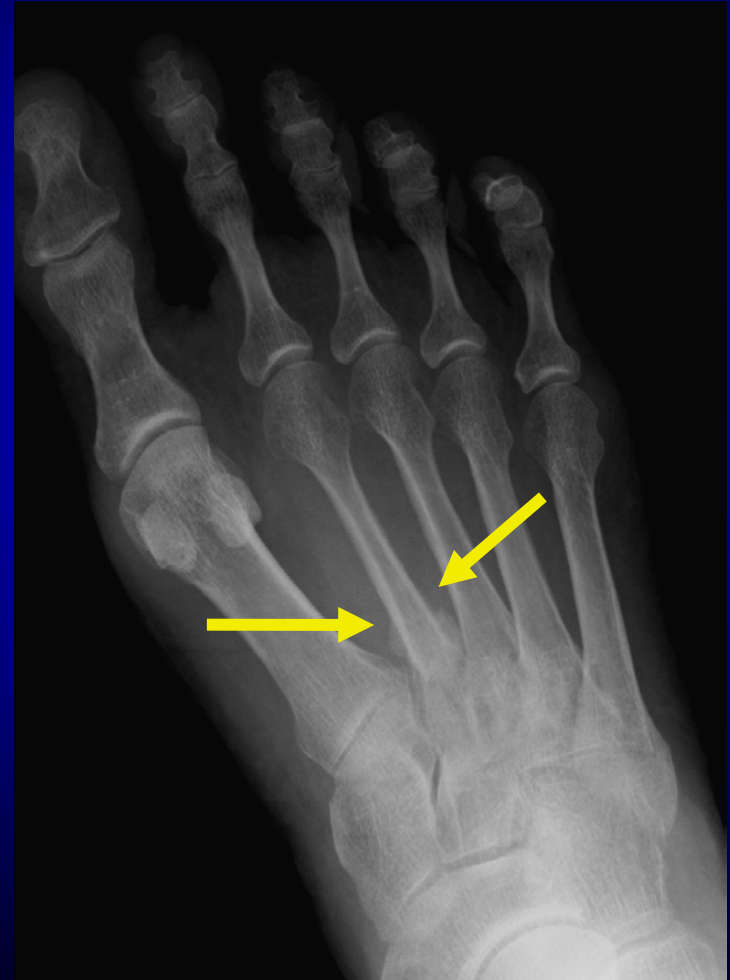

# Case # 12: Second Metatarsal Fracture

- Appearance:
  - Focal cortical step-off or cortical irregularity with local pain → highly suspicious
  - Color Doppler: Increased hyperemia
- Correlation with radiographs



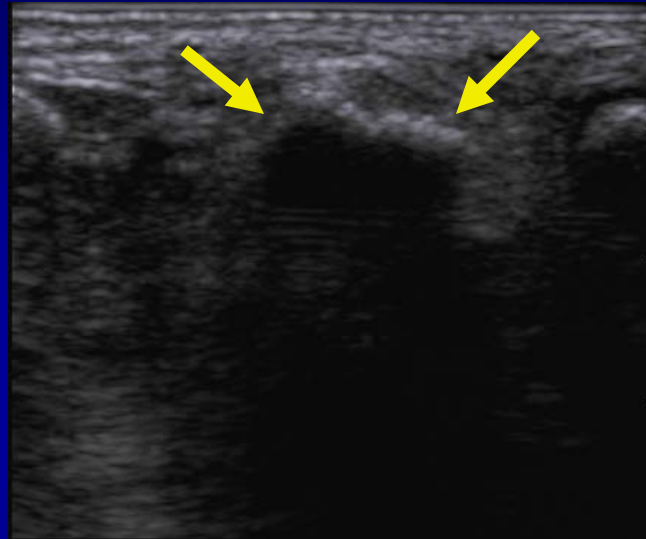
Longitudinal



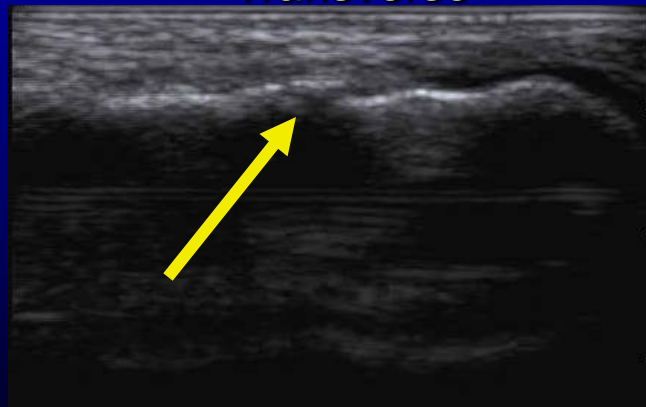


# Case # 13: Third Metatarsal Fracture

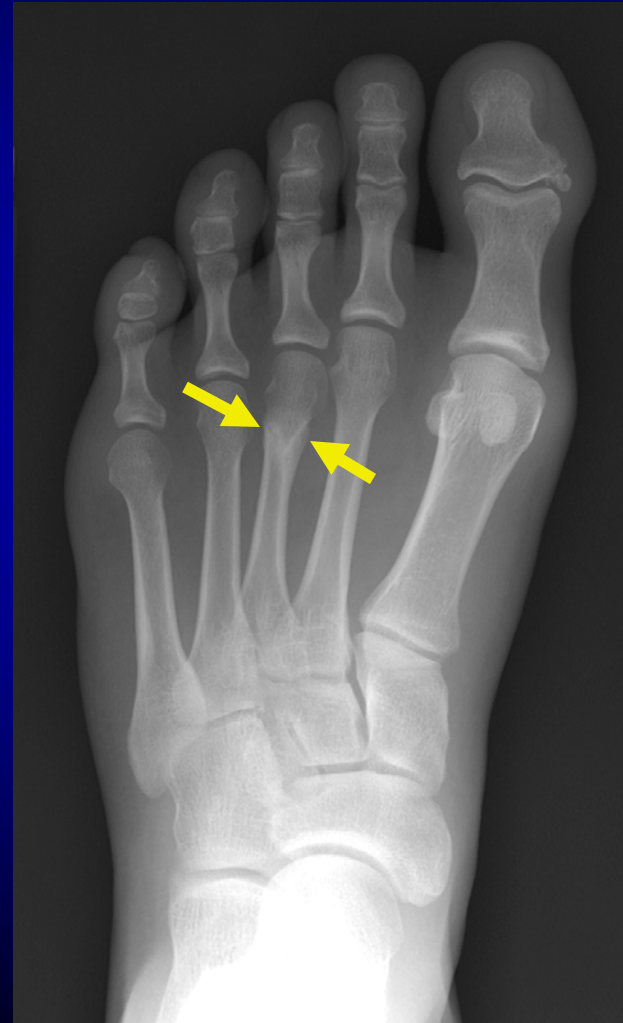---



Transverse



Longitudinal



# Conclusion

---

- Ultrasound is of great value in the evaluation of ankle and foot pathology
- Dynamic imaging
- Direct correlation with site of pain
- Comparison with opposite asymptomatic site

---

**Thank You**