

Imaging of total colonic Hirschsprung disease

Enno Stranzinger · Michael A. DiPietro ·
Daniel H. Teitelbaum · Peter J. Strouse

Received: 5 May 2008 / Revised: 13 June 2008 / Accepted: 1 July 2008 / Published online: 5 August 2008
© Springer-Verlag 2008

Abstract

Background Hirschsprung disease (HD) is a functional obstruction of the bowel caused by the absence of intrinsic enteric ganglion cells. The diagnosis of total colonic HD (TCHD) based on contrast enemas is difficult in newborns because radiological findings vary.

Objective To evaluate the radiographic and contrast enema findings in patients with pathologically proven TCHD.

Materials and methods From 1966 to 2007, 17 records from a total of 31 patients with TCHD were retrospectively evaluated for diameter and shape of the colon, diameter of the small bowel, bowel wall contour, ileal reflux, abdominal calcifications, pneumoperitoneum, filling defects, transitional zones and rectosigmoid index.

Results Three colonic patterns of TCHD were found: microcolon, question-mark-shape colon and normal caliber colon. Additional findings included spasmodic colon, ileal reflux, delayed evacuation and abdominal calcifications. Colonic transitional zones were found in eight patients with TCHD.

Conclusion The diagnosis of TCHD is difficult to establish by contrast enema studies. The length of the aganglionic small bowel and the age of the patient can influence the radiological findings in TCHD. The transitional zone and the rectosigmoid index can be false-positive in TCHD. The

colon can appear normal. Consider TCHD if the contrast enema study is normal but the patient remains symptomatic and other causes of distal bowel obstruction have been excluded.

Keywords Total colonic Hirschsprung · Contrast enema · Abdomen · Aganglionosis

Introduction

Hirschsprung disease (HD) is a functional obstruction of the bowel caused by a congenital absence of intrinsic enteric ganglion cells involving varying lengths of colon and small bowel. Several investigators have suggested that HD is caused by a lack of migrating ganglion cells. The timing of inhibition of migration results in aganglionosis of parts of the bowel. If the neural crest cells are inhibited as early as the 8th gestational week, the colon is affected and the ileum remains unaffected. In the 9th week, the descending colon and rectosigmoid are affected. If migrational inhibition is delayed until the 10th and 12th week of gestation only the rectosigmoid is affected [1]. Typically the aganglionic colon is small in caliber, contracted and spasmodic, and the more proximal bowel containing ganglion cells is dilated. Poor colonic motility leads to a clinical presentation with failure to pass meconium, abdominal distention and bilious vomiting. Complications include constipation, enterocolitis and bowel perforation.

The majority of children with HD have aganglionosis limited to the rectal, rectosigmoid or sigmoid regions [2]. Total colonic HD (TCHD) is characterized by aganglionosis of the entire colon and can involve the small bowel. TCHD is rare and accounts for approximately 3–12% of infants with HD [3]. An unprepped contrast enema might suggest

E. Stranzinger · M. A. DiPietro (✉) · P. J. Strouse
Section of Pediatric Radiology,
University of Michigan Health System,
1500 E. Medical Center Drive,
Ann Arbor, MI 48109-0252, USA
e-mail: dipietro@med.umich.edu

D. H. Teitelbaum
Section of Pediatric Surgery,
University of Michigan Health System,
Ann Arbor, MI, USA

the diagnosis, but suction or full-thickness rectal biopsy is needed to confirm the diagnosis of HD. The contrast enema is useful in deciding the operative approach [4]. Unfortunately, in TCHD there are no specific radiological signs described and the diagnosis might be suspected in only 20–30% of patients [3].

The continuing essential problem in total colonic aganglionosis is not the surgical management of the condition but rather its prompt diagnosis and the handling of the neonatal intestinal obstruction to decrease mortality [5]. This can be particularly challenging during a neonatal pull-through, when the surgeon is reliant on intraoperative frozen section histological diagnosis to determine the level of transition from colon with ganglion cells to colon without ganglion cells. Further, unlike shorter segment aganglionosis, the degree of nerve hypertrophy is much less, making interpretation of frozen sections more difficult [6]. Thus, preoperative findings that might raise the suspicion of TCHD are critically needed. This would allow for a more prompt evaluation of the colon, with biopsies of the right colon, appendix and ileum near the beginning of the case, which would thus reduce operative time as well as potentially prevent an incorrect determination of the transition zone at the time of pull-through. We describe here our long-term experience with radiographs and contrast enemas in establishing the diagnosis of TCHD in neonates.

Materials and methods

We received institutional review board approval for this retrospective study.

From 1966 to 2007, a total of 31 patients were treated for TCHD at our institution. The patients were identified via the pediatric surgery Hirschsprung database and from radiology case logs. Of the 31 patients, 16 had presurgical abdominal radiographs and contrast enema studies that were available for this review. In one patient, the medical records and the surgical and radiological reports were available for review, but not the images. The remaining 14 patients were excluded because the initial radiographs or enema studies were not retrievable because the patients were transferred from outside institutions, the radiological films were too old and predated the archival system, or the patients did not have a presurgical contrast enema study.

All 17 patients received a contrast enema, which included a scout abdominal radiograph. The more recent enema studies were performed with water-soluble rectal contrast material (Cysto Conray II, iothalamate meglumine; Mallinckrodt, St. Louis, MO); the older studies were with barium. In all patients, contrast material flowed by gravity into a taped catheter without an inflated rectal balloon. All

available initial radiographs, enema studies and delayed radiographs were evaluated by three pediatric radiologists. The final category of colon pattern was assigned by consensus.

Definitions

Rectosigmoid index	The rectosigmoid index was first described by Pochaczewsky and Leonidas [7] and is obtained by dividing the widest diameter of the rectum by the widest diameter of the sigmoid loop when the colon is fully distended by contrast medium. The normal rectosigmoid index is ≥ 1 . In standard-length HD the rectosigmoid index is ≤ 1 .
Transition zone	The transition zone on contrast enema is regarded as the site of obvious caliber change during the retrograde flow of contrast material from nondilated to dilated bowel [8–10].
Microcolon	A microcolon is a small-caliber colon, seen in the neonate on radiographic contrast enemas. Because there is no reported measurement standard available for microcolon, we included all colons with the largest diameter less than 1 cm, when the colon was fully distended by contrast medium.
Question-mark-shape colon	The question-mark-shape colon is described as a rounded and shortened contour of hepatic and splenic flexures with short-appearing colon [3, 11]. In addition to this finding, we included all proximal distended colons with continuous narrowing to the distal colon when the colon was fully distended by contrast medium. Others have described this unique configuration of the large bowel as a comma-shape colon [12, 13].
Normal colon	The normal, nondistended colon is usually less than 1 cm in diameter without contrast medium. When distended with contrast medium, the rectum is usually wider than the colon and the colon is more than 1 cm in diameter. At birth the tenia coli are not well developed, the walls are thin because of poor muscular development, and their external surfaces are smooth even when they are empty and

	contracted because they lack sacculations (haustra) [14].
Filling defects	Displacement of contrast medium by a space-occupying lesion in a radiographic study of a contrast-filled hollow viscus, such as meconium plugs on a contrast enema.
Clinical outcome	The clinical outcome was evaluated by a surgical score (good, fair, poor, died) including these parameters: recurrent abdominal distention, frequency of defecation, stool consistency, soiling, urgency, diapers required, chronic use of laxatives, postoperative complications, and clinical evaluation of the overall result.

Results

The mean age at the time of the enema study was 24 days with a median age of 4 days (range 1–90 days), and 15 of the patients were term infants, and two were preterm. There were 12 boys and 5 girls. The clinical presenting signs and symptoms included distended abdomen or obstructed bowel (16/17), delayed meconium passage (8/17), vomiting (8/17), diarrhea (2/17) and prolapsed rectal tissue (1/17).

Plain radiographs

All abdominal plain films showed moderate to marked bowel distention. In one patient, diffuse, tubular intraluminal calcifications in the right lower quadrant were noted. No pneumoperitoneum or pneumatosis was seen (Fig. 1).

Contrast enema, colon shape and caliber

Three shapes of the colon were found among the 16 patients with available images:

1. Microcolon-shape was found in four patients (24%) (Fig. 2). One patient with microcolon also showed tubular intraluminal calcifications. One patient with microcolon was preterm.

One patient with microcolon had long-segment aganglionosis of the colon but only partial involvement of the cecum and showed an unused, pencil-thin descending colon with a markedly distended, gas-filled transverse colon. Contrast agent did not reach the transverse colon (Fig. 3).

2. Normal-shape colon was found in nine patients (53%) (Fig. 4). In two of these patients a transition zone was noted, although the diameter on each side appeared within normal limits. In one patient with a normal-size

descending colon, the transverse colon was markedly distended and contrast agent did not reach the transverse colon. Seven colons appeared featureless without apparent haustra.

3. A question-mark-shape colon was noted in three patients (18%). The length of the question-mark-shape colon appeared short because of the dilated, round and smooth hepatic and splenic flexures (Fig. 5). In all three patients a gradual transition zone was noted.

Contour

A smooth or featureless contour of the colon was found in 12 patients. Mild to marked irregularity of the colon consistent with spasms was found in five patients, which was often more obvious on the post-evacuation film (Fig. 6).

Filling defects and ileal reflux

Filling defects were found in 12 patients (Fig. 7). Ileal reflux was noted in eight patients (Fig. 8). In two patients, ileal reflux could not be excluded because there was residual contrast agent from a prior upper gastrointestinal tract study.

In 14 patients, contrast agent filled the entire colon. In three patients, contrast filled only the rectum, sigmoid and descending colon. Two patients showed a markedly gas-

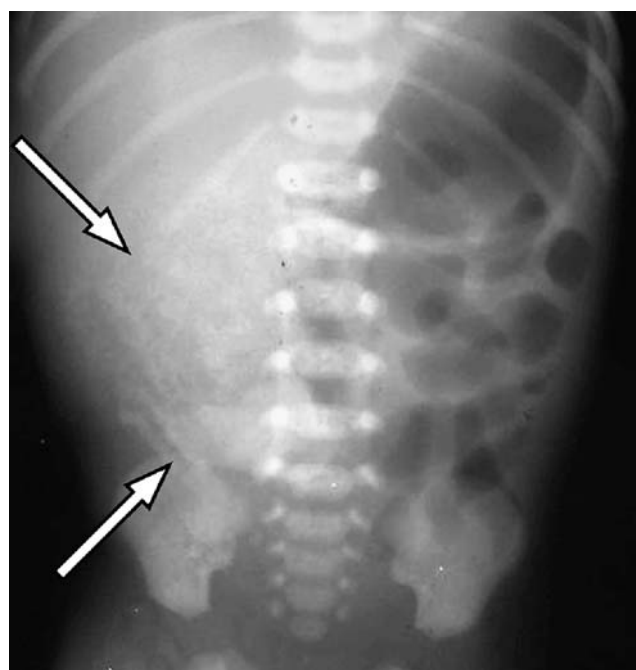


Fig. 1 Preterm baby with jejunal aganglionosis. Abdominal tubular intraluminal calcifications are noted in the right lower quadrant (arrows) with paucity of bowel gas. Bowel distention is noted in the left hemiabdomen

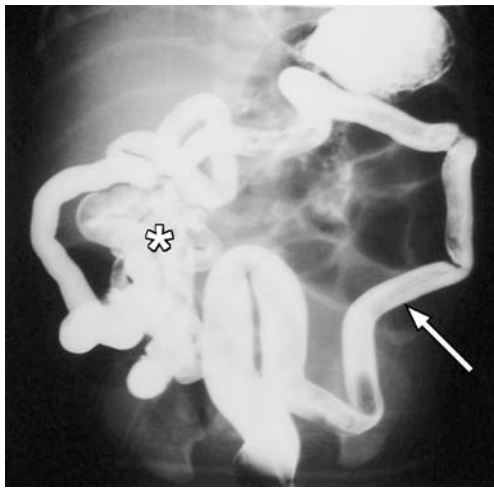


Fig. 2 Abdominal distention in a 1-day-old term baby. Enema shows a microcolon (*arrow*) with smooth contour and linear striation. Ileal reflux is noted (*asterisk*). Contrast agent in the stomach is noted from prior upper gastrointestinal tract study. Pathology confirmed aganglionosis involving the ileum and colon

distended and one a stool-filled transverse colon (Figs. 3 and 7).

Rectosigmoid index

The rectosigmoid index was <1 in ten patients and >1 in six patients. In one patient, for whom only the medical record was accessible, the index was not reported.

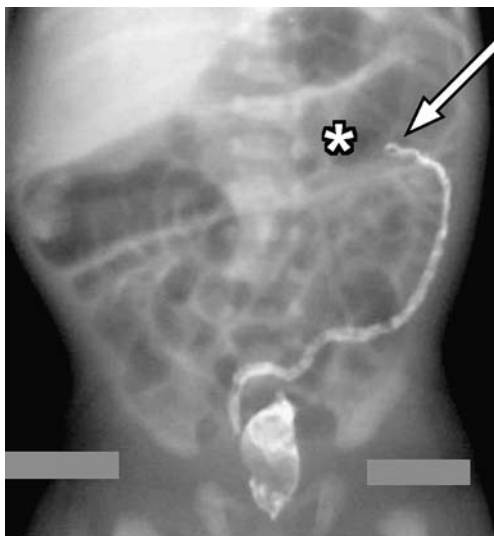


Fig. 3 Preterm baby with jaundice, vomiting, no stools and respiratory distress. An unused, thin microcolon is noted, when fully filled with contrast agent. The arrow indicates a transition between unused descending colon and gas-filled distended transverse colon (*asterisk*). Multiple histological sections of the colon were obtained and the entire colon except the cecum was aganglionic

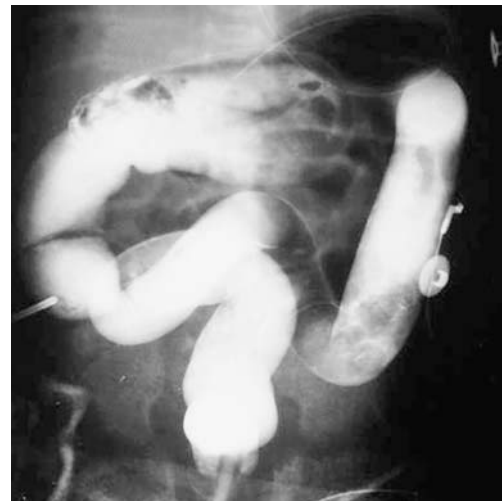

Fig. 4 A 2-day-old term baby with normal-caliber colon without transition zone and redundant ascending and transverse colon

Transition zone

A transition zone is a classic radiological sign in rectosigmoid HD. However, the three patients with a question-mark-shape colon and TCHD might be described as having a long transition zone colon with continuous narrowing from the cecum to the rectum (Fig. 8). These three patients lacked ganglion cells in the transverse colon and were pathologically proven to have TCHD.

In two patients, a short transition zone at the splenic flexure between a marked and gas-filled transverse colon and a contrast-filled normal shape or microcolon shape of the descending colon was noted (Fig. 3).

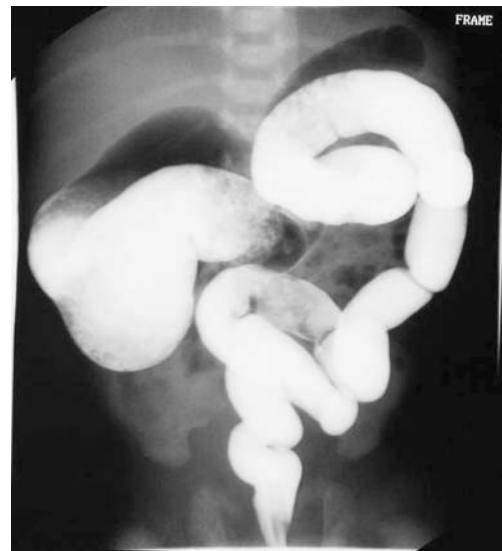

Fig. 5 Total colonic aganglionosis in a 3-day-old baby. Question-mark shape of the colon is noted with dilated cecum and ascending colon with continuous narrowing to the rectum. The rectum has normal caliber and appearance

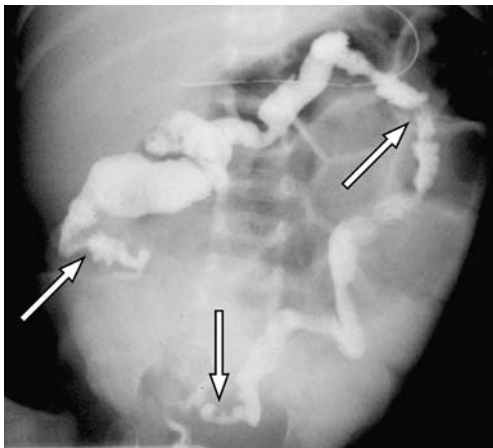


Fig. 6 A 43-day-old term baby. The 15-h delayed film shows incomplete contrast agent evacuation and irregular, spasmodic colonic contour or possibly collapsed colon (*arrows*). Gas-filled distended small bowel loops are noted. The baby had total colonic aganglionosis

Pathologically proven length of aganglionosis

Ten patients had total colonic aganglionosis only, four patients also had ileal involvement, one patient had pathology extending to the jejunum, and one patient was aganglionic from the pylorus to the anus (Table 1). One patient was included in the study who had long-segment HD of the colon except involvement of the cecum. One preterm infant with jejunal involvement showed abdomi-

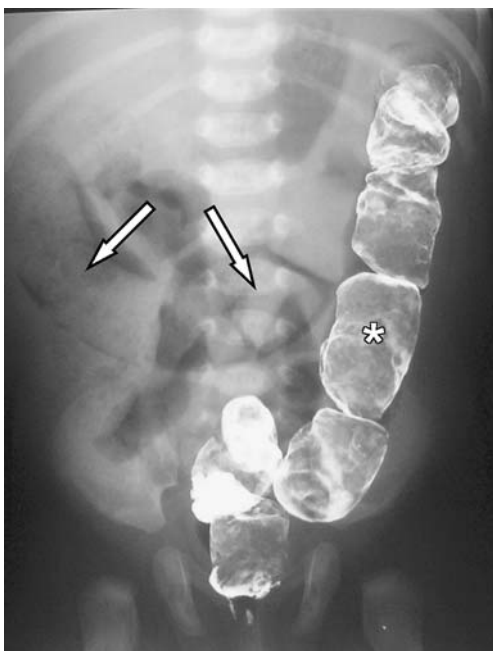


Fig. 7 Full-term 51-day-old girl with dilated colon and multiple filling defects (*asterisk*) and spasmodic narrowing of the descending colon. Stool-filled transverse colon without contrast agent is noted (*arrows*)

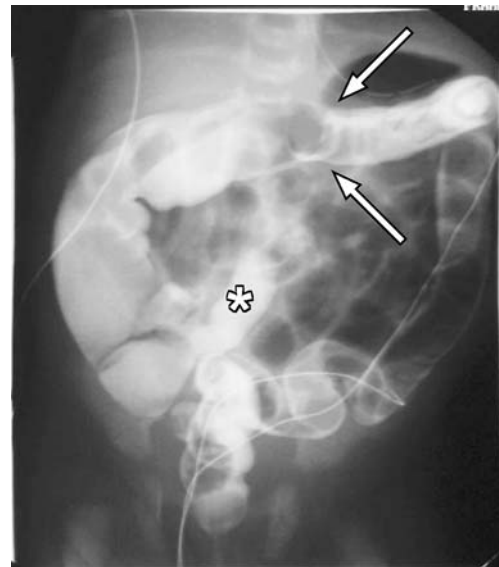


Fig. 8 Full-term 2-day-old boy with TCHD. False-positive transition zone is noted at the transverse colon (*arrows*) with distended ascending colon and proximal transverse colon. Ileal reflux is noted (*asterisk*)

nal tubular intraluminal calcifications and a microcolon (Fig. 1).

Clinical outcome

Of the ten surviving patients the clinical outcome was good in eight, fair in one and poor in one. Four patients died (two with microcolon and one who also had abdominal tubular intraluminal calcifications). One of the nonsurviving babies was 26 weeks premature and had Down syndrome and bronchopulmonary dysplasia. Two babies died with a normal-caliber colon with the contrast enema done at age 80 days and 90 days, respectively. No medical records were available in three patients concerning the clinical outcome.

Other congenital anomalies associated with TCHD in our patients were Down syndrome (one patient), Ondine syndrome (central hypoventilation syndrome), Smith-Lemli-Opitz syndrome, ambiguous genitalia, hydrocephalus or microcephalus and cardiac diseases such as patent ductus arteriosus, ventricular septal defect, and atrial septal defect.

Discussion

Major advances in genetics and neurophysiology and definitive management of the newborn with TCHD including treating HD-associated enterocolitis and laparoscopic and perineal approaches for the definitive pull-through and redo pull-through operations have occurred [3]. The mortality rate declined from 80% through the 1960s [15], to 68% through the 1970s and 1980s [16], to 13% in the

Table 1 Correlation of aganglionic length of colon and small bowel with the shape of the colon, tubular intraluminal calcifications and clinical outcome.

Patient	Gestation	Age at enema (days)	Length of aganglionosis	Calcification	Question mark	Normal caliber	Microcolon	Outcome
1	Term	5	TCH, no cecum	No			x, unused colon	NA
2	Preterm	No data	TCH	No	x			NA
3	Term	2	TCH	No	x			Good
4	Term	3	TCH	No	x			Poor
5	Term	80	TCH	No		x		Died
6	Term	60	TCH	No		x		Good
7	Preterm	90	TCH	No		x		Died
8	Term	1	TCH	No		x		Good
9	Term	1	TCH	No		x		Good
10	Term	7	TCH	No		x		NA
11	Term	43	TCH	No			x, post-evacuation	Good
12	Term	2	Ileum	No		x		Good
13	Term	51	Ileum	No		x		Good
14	Term	34	Ileum	No		x		Good
15	Term	1	Ileum	No			x	Fair
16	Preterm	4	Jejunum	Yes			x	Died
17	Term	3	Pylorus	No			x	Died

NA not available, TCH total colon involvement of HD with normal small bowel.

late 1990s. More recent series show that the vast majority of children with TCHD survive, which is dependent upon early diagnosis [17]. In rectosigmoid HD the classic radiological findings of transition zone point to the correct diagnosis with an accuracy of 90% [18] and a rectosigmoid index does so with an accuracy of 79% [19]. Although numerous case reports and a few retrospective studies of the roentgenographic manifestation of TCHD exist [5, 11, 12, 16, 20–30], little development has occurred in the radiological evaluation of TCHD in the last several years.

Because only a few patients with TCHD were premature, complications from immature bowel (necrotizing enterocolitis, strictures, bowel perforation) were otherwise unlikely. Most of our patients presented clinically with bowel obstruction, delayed meconium passage and emesis, as reported in the literature [17, 31]. The aim of the contrast enema study is to evaluate all possibilities of distal bowel obstruction including meconium plug syndrome (small left colon syndrome), meconium ileus, atresia, stenosis or HD.

Radiographs and contrast enema studies remain the imaging modalities of choice in the newborn with distal bowel obstruction.

Abdominal radiographs

An initial AP abdominal plain radiograph is indicated to demonstrate the bowel gas distribution, bowel distention and calcifications, and to rule out bowel perforation. In newborns, the paucity of colonic haustra impedes differen-

tiation of small bowel from large bowel [12]. Findings described in TCHD include intestinal obstruction with gas–fluid levels and gaseous distention of bowel loops [11, 16, 32]. All patients in our study presented with bowel distention, and one preterm infant presented with abdominal tubular intraluminal calcifications. The latter patient had jejunal aganglionosis with microcolon and later died.

Cowles et al. [33] reported six patients with right lower quadrant intraluminal calcifications, microcolon and long-segment intestinal aganglionosis. Such patients are often erroneously treated for meconium ileus [33]. In regard to intraluminal calcifications, Berdon et al. [34] reported five patients with imperforate anus and stated that intraluminal calcifications might develop in areas of prolonged stasis and enterovesical fistulas. Intraluminal calcifications can also occur in newborns with anorectal malformations and multiple gastrointestinal atresias [35, 36]. Extensive radiographic calcification is also seen in cystic fibrosis with meconium ileus, where it is more likely to represent intramural rather than serosal or intraluminal calcification [37]. In our series, no free abdominal gas was noted, nor did perforations occur during the enema study. In contrast, Newman et al. [29] reported that long-segment or total colonic aganglionosis accounted for 61% of documented cases of HD that presented with bowel perforation.

Contrast enema findings in TCHD

Fekete et al. [5] reported that the radiological findings in TCHD are nonspecific and allow only the recognition of a

functional ileal obstruction. They described seven normal colons and five small and comma-shape colons, lacking the normal flexures in the sigmoid, splenic and hepatic regions. In two patients, the ascending colon was distended and full of meconium [5].

Microcolon is often described in TCHD and occurs in 23–38% of patients, which corresponds to 4/17 patients in our series [11, 12, 16, 38]. Microcolon is also seen in patients with meconium ileus, distal jejunal, ileal, or proximal colonic atresia, and in megacystis-microcolon-intestinal hypoperistalsis syndrome [21]. Otherwise, the finding of microcolon warrants evaluation for TCHD. A normal-caliber colon is found in 22–77% of patients with TCHD and was found in 9/17 patients in our series, in which most of the normal-caliber colons had a smooth, featureless contour [11, 16, 39].

Coran and Teitelbaum [3] and others have described a question-mark-shape colon in TCHD with rounded edges of the splenic and hepatic flexures. Others have described this colon as a comma-shape or short colon with loss of the normal redundancy of flexures [12]. We found three patients with a question-mark-shape colon, in whom the cecum and ascending colon were significantly dilated with a continuous gradual narrowing to the rectum and, in addition, rounded splenic and hepatic flexures.

A transition zone was noted in eight patients with TCHD, including all three patients with a question-mark-shape colon. This finding should be interpreted as a false-positive finding, because the entire colon is aganglionic. A transition zone in TCHD could represent the presence of higher pressures and consecutive increased distention of the proximal colon compared to the more distal colon because of a functional obstruction with a pressure gradient or because of impacted meconium in the more distal colon. Nevertheless, our findings indicate that the colonic transition zone in HD does not correlate with the histological change between ganglionic and aganglionic bowel.

Siegel et al. [40] reported that a rectosigmoid index higher than 0.9 might rule out a diagnosis of rectosigmoid aganglionosis but might be falsely normal in longer-segment or total-colon aganglionosis [40]. We found six patients with a normal rectosigmoid index and ten patients with an abnormal rectosigmoid index. Our results demonstrate that the rectosigmoid index and the transition zone are not reliable signs to diagnose TCHD.

Most patients showed a smooth or featureless contour of the colon, which can be normal in newborns [14]. Five patients showed a spasmodic, irregular contour of the colon. Three of our five patients with spasmodic colon were between 43 and 60 days old at the time of the enema study. In a series of 13 patients, De Campo et al. [11] reported colonic wall irregularities in 46%.

Ileal reflux is often reported in TCHD, but it is a nonspecific finding in newborns. De Campo et al. [11] reported ileal reflux in 33% of patients with TCHD, which corresponds with our results. Ileal reflux also depends on the amount and pressure of the rectal contrast agent used during the enema. Cremin and Golding [41] emphasized the finding of rapid reflux of contrast material into the terminal ileum in patients with TCHD. Post-evacuation films and delayed films can show incomplete or delayed emptying of the contrast agent and spasmodic contractions. Sane and Girdany [16] noted prolonged retention of contrast agent in 21% of patients with TCHD [16]. Frech [42] described the “choppy wave” contour, which represents small contractions in the aganglionic segment. These findings were more apparent on the delayed images [42].

A history of delayed meconium passage, clinical findings of distended abdomen and bilious emesis, and radiological findings from radiography and enema add important information for the diagnosis of HD and TCHD. The radiological findings in TCHD are varied and sometimes mimic the more common causes of small intestinal obstruction in the newborn period leading to incorrect surgical therapy [31]. Often, the babies are treated for cystic fibrosis, constipation or meconium plugs. Once the enema study is reported as normal, the patient could present months or years later with enterocolitis and complications from undiagnosed HD. Probably all roentgenographic findings described in our study reflect the pathophysiology of TCHD. The different lengths of small bowel involvement, fetal bowel perforation or calcification and the age of the patient at presentation affect the imaging pattern. It remains unclear why the colon in patients with TCHD can be normal-caliber or distended.

Limitations

Although this retrospective study was one of the largest series of TCHD spanning 41 years, the number of patients with available enema studies was still limited to 17 patients. We did not compare the findings of TCHD with a control group of age-matched patients with colonic obstructions, but we reviewed the literature for diseases mimicking TCHD. This review was based on hard-copy radiographs, which did not allow real-time analysis of motility and spasticity of the colon. Such findings on contrast enemas can now be stored and reviewed with “cine-loops” on PACS systems.

Conclusion

TCHD is a rare but treatable cause of neonatal low-bowel obstruction. Plain films of the abdomen and contrast enema

are the initial radiological examinations of choice in newborns presenting with clinical signs of distal bowel obstruction. In TCHD the imaging findings differ significantly from those in short-segment HD. Varied imaging patterns are described in the literature. The rectosigmoid index and the transitional zone are not reliable signs of HD in patients with total colonic involvement. The enema might be normal. Important clinical predictors of TCHD, even if the enema is normal or false-positive for short-segment HD, are delayed meconium passage, bilious emesis, abdominal distention, a positive family history of HD and some genetic diseases and syndromes. Biopsy is warranted to confirm HD. Contrast enema cannot exclude the need for a biopsy if HD is possible. Consider TCHD if the contrast enema study shows the imaging pattern of TCHD described in this report. Also consider TCHD if the contrast enema study is normal but the patient remains symptomatic and other causes of distal bowel obstruction have been excluded.

References

- Zutshi M, Hull T (2006) Constipation, etiology, evaluation, and management. Springer, London
- Swenson O, Sherman JO, Fisher JH (1973) Diagnosis of congenital megacolon: an analysis of 501 patients. *J Pediatr Surg* 8:587–594
- Coran AG, Teitelbaum DH (2000) Recent advances in the management of Hirschsprung's disease. *Am J Surg* 180:382–387
- Martucciello G, Pini Prato A, Puri P et al (2005) Controversies concerning diagnostic guidelines for anomalies of the enteric nervous system: a report from the fourth International Symposium on Hirschsprung's disease and related neurocristopathies. *J Pediatr Surg* 40:1527–1531
- Fekete C, Ricour C, Martelli H et al (1986) Total colonic aganglionosis (with or without ileal involvement): a review of 27 cases. *J Pediatr Surg* 21:251–254
- Shaw PA (1990) The innervation and neuroendocrine cell population of the appendix in total colonic aganglionosis. *Histopathology* 17:117–121
- Pochaczewsky R, Leonidas JC (1975) The "recto-sigmoid" index. A measurement for the early diagnosis of Hirschsprung's disease. *AJR* 123:770–777
- Berdon WE, Baker DH (1965) The roentgenographic diagnosis of Hirschsprung's disease in infancy. *Am J Roentgenol Radium Ther Nucl Med* 93:432–446
- Jamieson DH, Dundas SE, Belushi SA et al (2004) Does the transition zone reliably delineate aganglionic bowel in Hirschsprung's disease? *Pediatr Radiol* 34:811–815
- Svenson O, Neuhauser EBD, Pickett LK (1948) New concepts of the etiology, diagnosis and treatments of congenital megacolon (Hirschsprung's disease). *Pediatrics* 4:201–209
- De Campo JF, Mayne V, Boldt DW et al (1984) Radiological findings in total aganglionosis coli. *Pediatr Radiol* 14:205–209
- Berdon WE, Koontz P, Baker DH (1964) The diagnosis of colonic and terminal ileal aganglionosis. *Am J Roentgenol Radium Ther Nucl Med* 91:680–689
- Escobar MA, Grosfeld JL, West KW et al (2005) Long-term outcomes in total colonic aganglionosis: a 32-year experience. *J Pediatr Surg* 40:955–961
- Crelin ES (1973) Functional anatomy of the newborn. Yale University Press, New Haven, pp 58–59
- Edelman S, Strauss L, Becker JM et al (1960) Universal aganglionosis of the colon. *Surgery* 47:667–677
- Sane SM, Girdany BR (1973) Total aganglionosis coli. Clinical and roentgenographic manifestations. *Radiology* 107:397–404
- Wildhaber BE, Teitelbaum DH, Coran AG (2005) Total colonic Hirschsprung's disease: a 28-year experience. *J Pediatr Surg* 40:203–206
- Proctor ML, Traubici J, Langer JC et al (2003) Correlation between radiographic transition zone and level of aganglionosis in Hirschsprung's disease: implications for surgical approach. *J Pediatr Surg* 38:775–778
- Garcia R, Arcement C, Hormaza L et al (2007) Use of the rectosigmoid index to diagnose Hirschsprung's disease. *Clin Pediatr (Phila)* 46:59–63
- Careskey JM, Weber TR, Grosfeld JL (1982) Total colonic aganglionosis. Analysis of 16 cases. *Am J Surg* 143:160–168
- Das Narla L, Hingsbergen EA (2000) Case 22: total colonic aganglionosis – long-segment Hirschsprung disease. *Radiology* 215:391–394
- Deffrenne P, Daudet M, Chappuis JP (1971) Radiology of total colonic forms of aganglionosis. *Ann Radiol (Paris)* 14:257–264
- Fletcher BD, Yullish BS (1978) Intraluminal calcifications in the small bowel of newborn infants with total colonic aganglionosis. *Radiology* 126:451–455
- Fondelli P, Martucciello G, Taccone A et al (1989) The radiologic picture of total colonic aganglionosis. *Radiol Med (Torino)* 77:207–210
- Guidone P, Thomason M, Buonomo C et al (1999) Pediatric case of the day. Total colonic Hirschsprung's disease. *AJR* 173:815, 819–820
- Jasonni V, Martucciello G (1998) Total colonic aganglionosis. *Semin Pediatr Surg* 7:174–180
- Lall A, Agarwala S, Bhatnagar V et al (1999) Total colonic aganglionosis: diagnosis and management in a 12-year-old boy. *J Pediatr Surg* 34:1413–1414
- Markham LA (2001) Total colonic aganglionosis: a case study. *Neonatal Netw* 20:23–29
- Newman B, Nussbaum A, Kirkpatrick JA Jr (1987) Bowel perforation in Hirschsprung's disease. *AJR* 148:1195–1197
- Tozzi A, Tramontano A, Toraldo C (1998) Clinical quiz. Long-segment Hirschsprung's disease (total colonic aganglionosis). *J Pediatr Gastroenterol Nutr* 27:546,559
- Coran AG, Bjordal R, Eek S et al (1969) The surgical management of total colonic and partial small intestinal aganglionosis. *J Pediatr Surg* 4:531–537
- Anupama B, Zheng S, Xiao X (2007) Ten-year experience in the management of total colonic aganglionosis. *J Pediatr Surg* 42:1671–1676
- Cowles RA, Berdon WE, Holt PD et al (2006) Neonatal intestinal obstruction simulating meconium ileus in infants with long-segment intestinal aganglionosis: radiographic findings that prompt the need for rectal biopsy. *Pediatr Radiol* 36:133–137
- Berdon WE, Baker DH, Wigger HJ et al (1975) Calcified intraluminal meconium in newborn males with imperforate anus. Enterolithiasis in the newborn. *Am J Roentgenol Radium Ther Nucl Med* 125:449–455
- Shen-Schwarz S, Fitko R (1990) Multiple gastrointestinal atresias with imperforate anus: pathology and pathogenesis. *Am J Med Genet* 36:451–455
- Taccone A, Marzoli A, Martucciello G et al (1992) Intra-abdominal calcifications in the newborn: an unusual case with

- anorectal malformation and other anomalies. *Pediatr Radiol* 22:309–310
37. Lang I, Daneman A, Cutz E et al (1997) Abdominal calcification in cystic fibrosis with meconium ileus: radiologic-pathologic correlation. *Pediatr Radiol* 27:523–527
38. Berdon WE, Baker DH, Santulli TV et al (1968) Microcolon in newborn infants with intestinal obstruction. Its correlation with the level and time of onset of obstruction. *Radiology* 90:878–885
39. Dorman GW (1957) Hirschsprung's disease; a lethal problem in early infancy. *AMA Arch Surg* 75:906–913
40. Siegel MJ, Shackelford GD, McAlister WH (1981) The rectosigmoid index. *Radiology* 139:497–499
41. Cremin BJ, Golding RL (1976) Congenital aganglionosis of the entire colon in neonates. *Br J Radiol* 49:27–33
42. Frech R (1968) Aganglionosis involving the entire colon and a variable length of small bowel. *Radiology* 90:249–257

Copyright of *Pediatric Radiology* is the property of Springer Science & Business Media B.V. and its content may not be copied or emailed to multiple sites or posted to a listserv without the copyright holder's express written permission. However, users may print, download, or email articles for individual use.